

# Surgical management of the diaphragmatic defect in congenital diaphragmatic hernia: a contemporary review

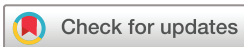Marietta Jank <sup>1,2</sup>, Michael Boettcher,<sup>2</sup> Richard Keijzer<sup>1</sup>

**To cite:** Jank M, Boettcher M, Keijzer R. Surgical management of the diaphragmatic defect in congenital diaphragmatic hernia: a contemporary review. *World J Pediatr Surg* 2024;**7**:e000747. doi:10.1136/wjps-2023-000747

► Additional supplemental material is published online only. To view, please visit the journal online (<https://doi.org/10.1136/wjps-2023-000747>).

Received 29 November 2023

Accepted 15 July 2024



© Author(s) (or their employer(s)) 2024. Re-use permitted under CC BY-NC. No commercial re-use. See rights and permissions. Published by BMJ.

<sup>1</sup>Division of Pediatric Surgery, Departments of Surgery and Pediatrics & Child Health, Max Rady College of Medicine, Rady Faculty of Health Sciences, University of Manitoba, Children's Hospital Research Institute of Manitoba, Winnipeg, Manitoba, Canada

<sup>2</sup>Department of Pediatric Surgery, University Medical Centre Mannheim, Heidelberg University, Mannheim, Germany

## Correspondence to

Dr Richard Keijzer; rkeijzer@hsc.mb.ca

## ABSTRACT

Worldwide, 150 children are born each day with congenital diaphragmatic hernia (CDH), a diaphragmatic defect with concomitant abnormal lung development. Patients with CDH with large defects are particularly challenging to treat, have the highest mortality, and are at significant risk of long-term complications. Advances in prenatal and neonatal treatments have improved survival in high-risk patients with CDH, but surgical treatment of large defects lacks standardization. Open repair by an abdominal approach has long been considered the traditional procedure, but the type of defect repair (patch or muscle flap) and patch material (non-absorbable, synthetic or absorbable, biological) remain subjects of debate. Increased experience and improved techniques in minimally invasive surgery (MIS) have expanded selection criteria for thoracoscopic defect repair in cardiopulmonary stable patients with small defects. However, the application of MIS to repair large defects remains controversial due to increased recurrence rates and unknown long-term effects of perioperative hypercapnia and acidosis resulting from capnothorax and reduced ventilation. Current recommendations on the surgical management rely on cohort studies of varying patient numbers and data on the long-term outcomes are sparse. Here, we discuss surgical approaches for diaphragmatic defect repair highlighting advancements, and knowledge gaps in surgical techniques (open surgery and MIS), patch materials and muscle flaps for large defects, as well as procedural adjuncts and management of CDH variants.

## INTRODUCTION

Congenital diaphragmatic hernia (CDH) is characterized by a diaphragmatic defect and abnormal lung development.<sup>1</sup> Defect size correlates with disease severity and survival.<sup>2-4</sup> Even though mortality has significantly decreased due to advances in neonatal management, surgical treatment with regard to defect size currently lacks standardization.

The basic concept of surgical treatment for CDH seems straightforward with reduction of herniated organs from the thorax into the abdomen and closure of the diaphragmatic defect. The traditional procedure is open

surgery with primary closure in small defects and patch repair in large diaphragmatic defects. Minimally invasive surgery (MIS) is increasingly used to repair CDH. The thoracoscopic approach is mainly considered in stable patients with small defects.<sup>1,5</sup> However, with improved techniques and increased surgical experience the indication for an MIS approach is shifting toward larger defects including those requiring patch repair.<sup>6-9</sup> This manuscript presents a scoping review of the surgical treatment of CDH defects, including current advances in MIS compared with open surgery, as well as future directions (please refer to online supplemental file 1 for the search strategy).

## DEFECT SIZE IN CONGENITAL DIAPHRAGMATIC HERNIA

In 2013, the CDH Study Group (CDHSG) developed a risk-stratified reporting system according to defect size<sup>10</sup>: an 'A' defect is surrounded entirely by muscle with >90% hemidiaphragm present, a 'B' defect has 50%–75% present, a 'C' defect <50% and a 'D' defect is a complete or near complete absent hemidiaphragm (<10%).<sup>10</sup> 'C' and 'D' defects are associated with a higher morbidity and mortality.<sup>2-4, 10</sup> In studies on outcomes, 'C' and 'D' defects are summarized as 'high-risk' or 'large defects'.<sup>4, 11</sup> Other publications on surgical repair consider a subgroup of 'B' defects as 'large'.<sup>6, 12</sup> Prior to the CDHSG defect classification, outcome research relied on factors suggestive of a large defect, such as early prenatal diagnosis, low observed/expected lung-to-head ratio, low total fetal lung volume, prenatal stomach-up or liver-up, postnatal liver-up and necessity of patch repair.<sup>13, 14</sup> Adherence to this risk-stratified reporting system will ensure future standardization of surgical indications and approaches.

## REPAIR OF SMALL CDH DEFECTS

In most diaphragmatic defects, primary closure is feasible. The primary aim is a tension-free repair, irrespective of surgical approach (MIS and open surgery) or technique. MIS has been shown to be a safe and feasible treatment in CDH and has potential benefits of reduced perioperative pain, a shorter hospital stay,<sup>15</sup> ventilation duration, time to enteral feeding, cosmesis and less frequent occurrences of adhesive bowel obstruction.<sup>16</sup> However, a recent systematic review shows a six times higher recurrence rate in MIS irrespective of defect size (MIS: 8.6% vs open repair: 1.4%).<sup>15</sup> This is in line with previous meta-analyses<sup>17–19</sup>; however, the studied groups show a bias in disease severity with more patch repair and higher mortality in the open repair group.<sup>15 18 19</sup> In the early descriptions of MIS repair of CDH, only cardiopulmonary stable neonates with small defects were considered.<sup>20 21</sup> Most publications do not account for defect size, but an increasing number of recent studies compare MIS and open repair in patients with a similar defect size.<sup>6 16</sup>

Selection criteria for MIS or open CDH surgery remain subjects of debate and depend on the surgeon's experience. Low-volume hospitals have significantly higher recurrence rates and hospital costs than high-volume centers.<sup>22</sup> Therefore, it has been argued that selection criteria for MIS may or even should differ depending on the volume of cases treated per center.<sup>9 23</sup> Centralization for management of complex CDH has been proposed to improve care and reduce costs, complications, morbidity, and mortality.<sup>13</sup> However, other factors are also associated with a higher recurrence in MIS (e.g., defect size, patch material).<sup>24–26</sup> Based on current evidence, it has

been suggested that thoracoscopic repair be restricted to cardiopulmonary stable patients with small to moderate ('A' or 'B') defects.<sup>5 9 10 16</sup>

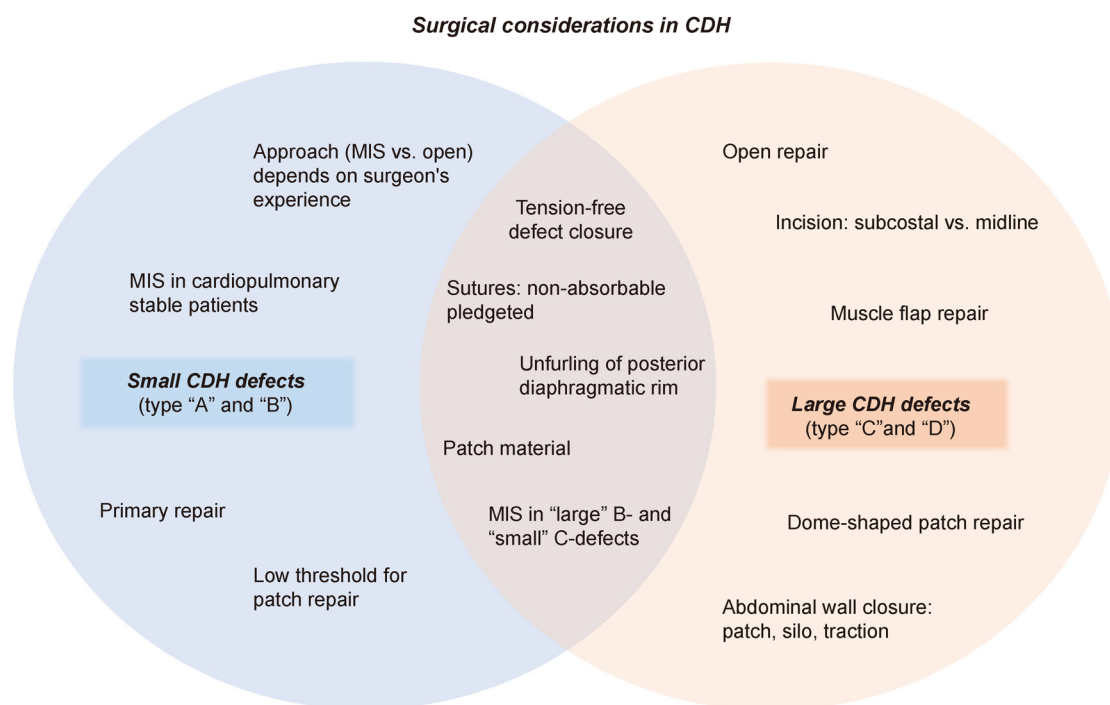
High recurrence rates after thoracoscopic repair may be explained by: (1) lack of experience in thoracoscopic repair, particularly if a patch is required<sup>17 27</sup>; (2) the magnifying effect of the endoscope leading to an underestimation of sutures between the diaphragm and the patch<sup>28</sup>; (3) challenges in equally distributing suture tension using MIS instruments<sup>29</sup>; and (4) difficulty achieving sufficient dissection and unfurling of the posterior rim (if it exists) to reduce tension.<sup>23</sup> The most common site of hernia recurrence is a small dehiscence between the diaphragm and patch in the posterolateral costodiaphragmatic recess.<sup>29</sup>

To reduce the risk of recurrence, some authors recommend traumatic abrasion of the defect rim to facilitate healing, rather than suturing two 'smooth' surfaces with an intact mesothelial lining to each other.<sup>25 30</sup> Non-absorbable sutures are recommended to secure the patch and pledgeted sutures can be used to strengthen the hold on diaphragmatic tissue in both the open surgery and MIS approach.<sup>6 13 31–33</sup> These techniques can be applied in CDH repair irrespective of defect size, but management of large CDH is technically challenging and requires alternative approaches (figure 1).

## REPAIR OF LARGE CDH DEFECTS

### Open surgery

Open repair remains the most common approach to large CDH defects not amenable to a tension-free, primary



**Figure 1** Patch materials used in congenital diaphragmatic hernia (CDH) defects not amenable to primary repair. MIS, minimally invasive surgery.

repair. Type of incision, defect closure (patch or muscle flap), shape of patch and technical adjuncts (antireflux surgery, abdominal wall closure) must be considered.

Repair of large CDHs requires optimal exposure of the defect achieved by a thoracic or abdominal (ie, subcostal and midline) incision. Thoracotomy was historically the most frequent approach, nowadays only 1%–5% of pediatric surgeons repair left-sided CDH via a thoracotomy.<sup>34 35</sup> Although a thoracic approach may facilitate placement of pericostal sutures, hence strengthening the patch repair, it is associated with an increased risk for musculoskeletal deformities and higher rate of surgical reinterventions within the first year of life, especially for severe acute gastrointestinal complications.<sup>34 36</sup>

The abdominal approach with a subcostal incision is preferred by most pediatric surgeons. A transverse upper quadrant incision is argued to provide the best exposure in neonates and to better withstand increases in intra-abdominal pressure, hence reducing the risk for an incisional hernia.<sup>37–39</sup> Conversely, Waag *et al.* have advocated for a vertical midline incision due to improved exposure of the defect,<sup>40</sup> option of increasing the incision beyond the umbilicus and improved cosmesis, with a possibly reduced risk of incisional hernia.<sup>41</sup>

### Patch repair

Patch repair is often used as a surrogate marker for large defects,<sup>35</sup> but it is unclear what type of patch material should be used: permanent (polytetrafluorethylene, PTFE), biosynthetic (eg, small intestinal submucosa, dermal collagen), or composite patches.<sup>42 36 43 44</sup> The types of patch material reported in the literature are summarized in [figure 2](#). Current evidence, mainly based

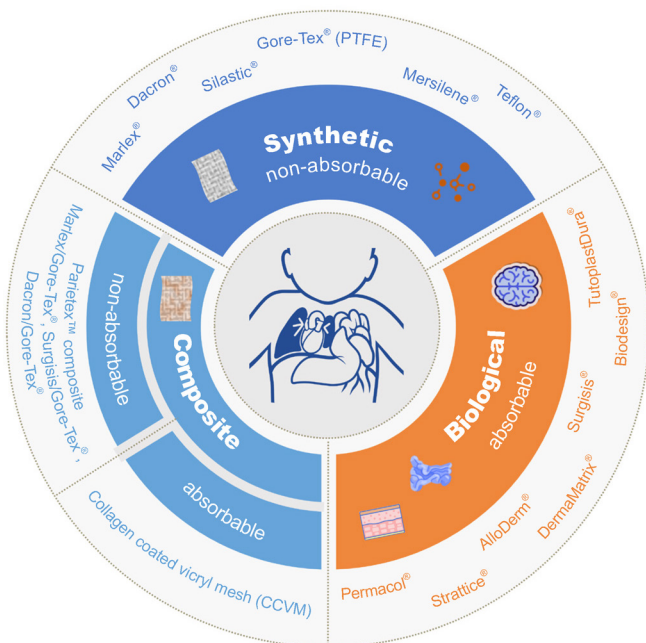
on cohort studies, recommends a non-absorbable PTFE/Gore-Tex patch (WL Gore and Associates, Newark, Delaware) because of its durability compared with biologically absorbable material.<sup>5 7 45–47</sup> However, studies show varying results.<sup>13 48–53</sup> A recent meta-analysis reported similar mortality rates, risk of adhesive bowel obstruction and incidence of gastroesophageal reflux disease (GERD) after synthetic and biological patch repair.<sup>49</sup> Among biologically absorbable materials, intestinal submucosal Surgisis (Cook Medical, Bloomington, Indiana) was one of the earliest patches, hence is the most studied in the literature to date.<sup>48 50–55</sup> Surgisis allows for full incorporation of the patch into the native tissue; however, resorption starts within 2 weeks which may explain the high recurrence rate due to insufficient scarring to withstand the abdominal pressure.<sup>49</sup> A recent industry refinement on Surgisis is Biodesign (Cook Medical), which displays faster rehydration and more blood vessel ingrowth. Permacol (Medtronic, Minneapolis, Minnesota) uses a cross-linked acellular porcine dermal collagen to improve long-term tensile strength.<sup>49 56</sup> Mitchell *et al.* showed no recurrence in eight cases after Permacol repair (median follow-up: 20 months) compared with a 29% recurrence rate after Gore-Tex patch repair (median follow-up: 57 months).<sup>56</sup> Unfortunately, sufficient data on the outcomes of newer materials are lacking, but the prospective multicenter cohort ‘Defect Study’ might provide answers in the future.<sup>57</sup>

The goal of a tension-free, oversized closure of the diaphragm is especially important in large defects. Synthetic patches do not grow with the patient, which can result in recurrence in the long term. An oversized ‘cone’-shaped patch provides additional abdominal domain which may offset the development of tension between the patch and defect edges, and in one study resulted in an equivalent recurrence rate to that of primary repairs.<sup>58</sup> ‘Cone’-shaped patches try to replicate the shape of the diaphragm to facilitate a more physiological thoracic volume, with improved respiratory physiology, and a lower recurrence rate.<sup>46 47</sup>

### Muscle flap repair

Muscle flap repair is suggested as an alternative approach in very large defects or recurrent CDH.<sup>55 59–68</sup> Even though reverse latissimus dorsi (RLD) and abdominal wall muscle flap repairs have been described since 1983 and 1962, respectively, studies on the application and outcome of muscle flap repairs are limited.<sup>68 69</sup>

An abdominal wall muscle flap is facilitated by a transverse or subcostal abdominal incision that is 2–3 cm below the costal margin which enables superior flap-based separation of the external and internal oblique muscle layers and closure of the diaphragmatic defect with the transversus abdominis-internal oblique muscle flap turned inward.<sup>67</sup> It is mainly used in initial repair of large defects in neonates.<sup>55 59–67</sup> The advantages are the potential for growth and the lack of a foreign body reaction. However, the required muscular dissection could result



**Figure 2** Technical considerations in congenital diaphragmatic hernia (CDH) repair. PTFE, polytetrafluorethylene.

in an abdominal wall bulge.<sup>65 67</sup> Large CDH defects are inherently associated with a higher risk of musculoskeletal deformities irrespective whether an abdominal wall muscle flap or patch is used.<sup>70</sup> The recurrence rate of this technique ranges from 0% to 20%.<sup>55 59 62 66 71</sup> Nasr *et al.* found no significant difference in chest wall deformities, bowel obstruction or mortality between patch ( $n=32$ ) or abdominal wall muscle flap ( $n=19$ ) repairs.<sup>55</sup> The largest study comparing abdominal wall muscle flap and patch repair showed no statistically significant difference in recurrence (abdominal wall muscle flap: 3.5%,  $n=2/57$  vs patch: 8.8%,  $n=3/34$ ).<sup>62</sup> Abdominal wall muscle flap repair is feasible on extracorporeal membrane oxygenation (ECMO), and there was no difference in on-ECMO bleeding complications compared with patch repair in small cohorts.<sup>59 63 65</sup> Only one study described the abdominal wall muscle flap in recurrent CDH repair; however, the benefit of this technique compared with others is unclear.<sup>64</sup>

An RLD muscle flap repair has several benefits: (1) sustained blood supply by lumbar-perforating vessels minimizing flap atrophy, (2) potential for 'neodiaphragmatic' function enabled by a phrenic to thoracodorsal neural anastomosis and (3) ability to grow with the child.<sup>60 68</sup> The anticipated hemodynamic instability associated with large defects and the longer operative time associated with an RLD muscle flap repair argues against its use for the initial repair.<sup>72</sup> An RLD muscle flap could be considered as an alternative in recurrent CDH or as a staged approach following patch repair resulting in recurrence, chest wall deformity or other thoracic complications.<sup>60 68 72</sup>

As an alternative to muscle flaps, Toldt's fascia flap repair has been described in seven patients with large defect, but long-term data or benefits of this technique—published in 2005—are absent.<sup>73</sup>

### Procedural adjuncts for large defects

Surgical management of large diaphragmatic defects may require consideration of procedural adjuncts compared with small defects (figure 1), including antireflux surgery and staged abdominal wall closure. Large defects have a higher risk of developing GERD requiring antireflux surgery later in life.<sup>74</sup> The incidence reported in the literature varies<sup>74–76</sup>: a study of 126 patients with CDH reported that 55.6% developed GERD and 33.3% received a fundoplication.<sup>74</sup> The apparent association of GERD requiring fundoplication with large defect CDH has prompted consideration of 'preventative' antireflux surgery at the time of CDH repair. A prospective, multi-institutional study showed no benefit to a preventative fundoplication during the initial patch repair in high-risk patients: it did not prevent—in fact, it increased—the likelihood of failure to thrive, the need for tube feeding, the occurrence of oral aversion and the necessity for curative redo fundoplication later in life.<sup>76</sup> Current evidence does not support a 'preventative' fundoplication at primary repair, and antireflux surgery or other antireflux

interventions should only be considered in the context of failed medical management.<sup>5 75 76</sup>

A potential difficulty at the end of the initial repair of large and occasionally small defects lies in the severity of visceros-abdominal disproportion which can present challenges to abdominal wall closure. A 'cone'-shaped diaphragmatic patch can partially compensate for a small abdominal cavity, creating an estimated 20 mL more volume.<sup>36</sup> However, in severe cases, a staged abdominal wall closure (e.g., temporary silo, patch) mitigates the risk of abdominal compartment syndrome and reduces the risk of early recurrence.<sup>77</sup> In MIS repair, tackling visceros-abdominal disproportion is more challenging and carries a higher risk of gastrointestinal complications. Hiradfar *et al.* describe a two-staged endoscopic repair of a large defect in a 4-month-old boy: a laparoscopic transverse fasciotomy was performed inducing an iatrogenic ventral hernia, and a pneumoperitoneum was maintained over 2 days until a thoracoscopic patch repair was possible.<sup>78</sup>

### Minimally invasive surgery

Minimally invasive repair has been shown to be safe and feasible for CDH, particularly for stable infants with small defects. With increased experience, many of the initial contraindications have been challenged or even refuted (e.g., stomach-up/liver-up,<sup>6 21</sup> 'C' defects,<sup>6 79</sup> need for patch,<sup>15</sup> right-sided CDH,<sup>23</sup> need for perioperative high-frequency oscillatory ventilation,<sup>80</sup> ECMO,<sup>9 81–84</sup> and associated anomalies<sup>85</sup>). Current recommendations mainly rely on cohort studies of varying size and quality, and data on long-term outcomes are sparse.

Threshold for a patch repair should be similar in MIS and open repair with a goal of achieving a tension-free closure.<sup>7 29 31 32 86</sup> Although higher recurrence risks have been associated with MIS (almost exclusively thoracoscopic) repair, increased experience has led to an observed decrease in recurrence rates.<sup>24 86</sup> Recent studies have shown a similar recurrence rate in thoracoscopic and open repair of selected patients.<sup>6 8 81 87</sup> In September 2023, Shah *et al.* published the first direct comparison of thoracoscopic and open repair of 'larger' CDH defects, defined as a 'B' defect with patch repair or a 'C' defect.<sup>6</sup> Even though the study tried to account for bias in disease severity, patients with open repair had a significantly lower observed/expected lung-to-head ratio, observed/expected total lung volume, more 'C' defects, liver-up and a greater ECMO necessity. Nonetheless, there was no difference in operative time, intraoperative acidosis and recurrence rate between MIS and open surgery.<sup>6</sup> Despite these findings, the authors proposed open repair in patients with 'D' defects, liver-up, ECMO necessity and high preoperative ventilation parameters.<sup>6</sup> Among pediatric surgeons, there is a call for prospective, multicenter registries and development of trials to identify which patients with CDH most clearly benefit from a thoracoscopic repair.<sup>22 36</sup>

Reduced risk of bowel obstruction would favor an MIS approach; but bowel obstruction has been studied

less than recurrence. Studies in small cohorts show a decreased bowel obstruction rate after thoracoscopic repair.<sup>9 52 88-91</sup> The CDHSG showed a five times lower risk of adhesive small bowel obstruction requiring an operation prior to discharge in thoracoscopic compared with open repair, but the number of 'C' and 'D' defects repaired by MIS was low.<sup>9</sup> Zahn *et al.* showed that small bowel obstruction after thoracoscopic repair was only associated with CDH recurrence and not adhesions, even in cases of thoracoscopic Gore-Tex patch repair.<sup>90</sup> This might be related to the reduced peritoneal irritation eliciting an inflammatory response (and therefore adhesions) in thoracoscopic repair.

#### Technical considerations in MIS repair of large defects

Evolution of MIS and improved surgical techniques resulted in decreased operative time and recurrence rates, but also expanded the selection criteria to more complex CDH cases. Safe reduction of herniated abdominal organs, suturing and tensionless defect repair are the main challenges of MIS in CDH repair. Several innovations have been suggested to facilitate the procedure.

To overcome the challenge of reduction, particularly in larger defects, studies have suggested insertion of more than three ports,<sup>33 86 92-94</sup> placement of mesh,<sup>6</sup> a temporary increase in CO<sub>2</sub> insufflation rate,<sup>86 92 94</sup> or transthoracic traction stitches in the middle of the defect to keep the organs reduced when suturing.<sup>93</sup>

Intracorporeal suturing remains one of the most difficult and time-consuming steps in the repair of moderate to large defects resulting in prolonged operative time and conversion to open repair. Several techniques have been described to facilitate thoracoscopic knot tying and can be categorized into intracorporeal<sup>84 95</sup> or extracorporeal.<sup>29 47 86 92-94 96 97</sup> He *et al.* described an extracorporeal technique combining a granny and surgeon's knot. They report no conversion to open repair or recurrence in 26 cases at a median follow-up of 13.7 months.<sup>97</sup> A similar extracorporeal-assisted intracorporeal method has been suggested with a sliding knot.<sup>98</sup> Further techniques include non-absorbable helicoidal tacks<sup>95</sup> and unidirectional barbed knotless sutures.<sup>84</sup>

Different techniques and devices have been described to aid pericostal suturing in MIS, particularly when no posterolateral diaphragmatic rim exists. The most common described technique is to pass a needle directly through a small incision in the skin, the intercostal space, the diaphragm or patch and then back through the same incision. The knot tying takes place extracorporeally and multiple knots can be buried in the subcutaneous tissue.<sup>25 26 32 81 99</sup> An alternative method is similar to the percutaneous internal ring suturing technique for inguinal hernia repair: different techniques and devices have been described to aid in the fixation of the diaphragm or patch to the ribs with mattress sutures.<sup>79 92-94 100</sup> Mansour *et al.* suggest anchoring the patch around the ribs using Endo Close.<sup>86</sup> Lapa-herclosure (Hakko, Chikuma, Japan) is a 19-gauge needle

with a built-in wire loop to hold and release sutures intracorporeally and to facilitate securing the patch around the ribs.<sup>29</sup> Michel *et al.* report a 'T-shaped' placement of sutures to achieve primary thoracoscopic repair in 'large B-defects' with close to 50% absence of the diaphragm; no recurrence occurred in any of the seven cases over a median of 3.5 years of follow-up.<sup>12</sup>

Different thoracoscopic patch onlay techniques have been proposed to reduce the higher recurrence rate observed in MIS. Most studies describe a 'cone'-shaped, single layer of Gore-Tex patch.<sup>29 31 32 81</sup> Alternatively, Kamran *et al.* proposed a double-layered repair of Marlex (Becton Dickinson, Franklin Lakes, New Jersey) (thoracic side) and Gore-Tex (abdominal side) mesh in 'larger' B defects, or leaving a hernia sac as a natural underlay to the prosthetic buttresses.<sup>33</sup> Shah *et al.* describe a sandwiched approach of Vicryl mesh (abdominal side) to facilitate reduction and induce scarring, and Gore-Tex on top.<sup>6</sup> A biological mesh (Surgisis) underlay has been proposed to reduce the recurrence rate in both thoracoscopic primary and patch repair.<sup>25 26</sup> Thoracoscopic repair with a single layer of biological mesh, Surgisis, resulted in early and frequent recurrences, hence is not advised.<sup>32</sup> Recently, a novel, self-expandable patch has been tested in an inanimate CDH model to successfully repair 'C' and 'D' defects.<sup>101</sup> A single case report describes using the Gerota fascia to repair a large defect thoracoscopically.<sup>102</sup> Technical innovation has driven the evolution of MIS in CDH improving operative times, outcomes especially in small defects, and reducing rates of conversion to open repair in larger defects. However, the variability in reported techniques and the very limited number of cases with follow-up makes it difficult to determine which approaches offer the greatest outcome benefit.<sup>22 33</sup>

#### Anesthetic considerations

The thoracoscopic approach to large defects increases intraoperative challenges for anesthetists due to potentially severe hypercapnia and acidosis caused by CO<sub>2</sub> insufflation which compresses and reduces ventilation of the already hypoplastic lung, and results in systemic CO<sub>2</sub> absorption. Intrathoracic pressures may be elevated by ventilatory pressure requirements compounded by CO<sub>2</sub> insufflation causing decreased venous return. In addition, patients with CDH with large defects have an increased oxygen demand due to their hypoplastic lungs.<sup>103</sup> Hypoxia, CO<sub>2</sub> accumulation and acidosis could further aggravate pulmonary hypertension, resulting in a vicious cycle.<sup>104</sup>

Intraoperative hypercapnia and acidosis have been described in multiple retrospective studies<sup>105-109</sup> and one pilot randomized controlled trial.<sup>110</sup> Other studies in small cohorts demonstrated no difference in hypercapnia and acidosis between MIS and open repair, even after ECMO.<sup>6 81 111</sup> A 'low pressure, slow insufflation technique' to establish capnothorax is suggested to allow the neonate to gradually adapt to the CO<sub>2</sub> insufflation and potentially avoid spikes in hypercapnia.<sup>32 105 108</sup>

The adverse effect of perioperative acidosis and hypercapnia on the long-term outcome remains controversial. Bishay *et al.* reported that intraoperative acidosis was associated with a decrease in cerebral hemoglobin oxygen saturation in six patients during thoracoscopic CDH or esophageal atresia/tracheoesophageal fistula repair that could potentially contribute to ischemic brain injury.<sup>109</sup> Okazaki *et al.* describe normal neurodevelopment after thoracoscopic repair, even though significant intraoperative hypercapnia and acidosis occurred.<sup>112</sup> Costerus *et al.* showed that intraoperative regional cerebral oxygen saturation remained within clinically acceptable limits during periods of acidosis, and neurodevelopmental outcomes (in those available for evaluation) at 24 months were within normal range.<sup>113</sup> Long-term outcomes beyond infancy are lacking; however, the attribution of morbidity to the surgical technique rather than to the known consequences of CDH pathophysiology will always be a challenge.

ECMO before thoracoscopic repair is feasible, but experience is limited.<sup>6 81–84 86</sup> Many surgeons consider intraoperative or preoperative ECMO a contraindication for thoracoscopic repair.<sup>114</sup> Nevertheless, Schlager *et al.* reported no increase in operative morbidity or mortality for six patients with successful thoracoscopic repair after ECMO with similar recurrence rates compared with open repair.<sup>82</sup> However, most post-ECMO patients with attempted MIS repair ( $n=15/21$ ) in the study were converted. Budzanowski *et al.* published a cohort of six post-ECMO patients with a thoracoscopic patch repair<sup>81</sup>; there was no significant difference in the perioperative blood gas parameters between thoracoscopic and open repair, but two of six patients were converted to open repair due to diaphragmatic agenesis.<sup>81</sup> Prenatal intervention with fetoscopic endoluminal tracheal occlusion has improved pulmonary hypoplasia in severe CDH cases contributing to reduced severity of pulmonary hypertension.<sup>115</sup> It can be speculated that improved pulmonary outcomes in these patients might encourage a greater shift from open surgery to MIS.

### Laparoscopy

Most studies on MIS in neonatal CDH only include the thoracoscopic approach.<sup>6 7 12 16 20 21 23 25 26 28–30 32 33 79–88 91–99 102 104–108 110 112 113</sup> The CDHSG showed that 17.2% of MIS in all CDH cases were performed using laparoscopy.<sup>35</sup> Possible benefits of laparoscopy are reduced risk of visceral injury, inspection for abdominal anomalies and easier conversion to an open approach. A case of laparoscopic patch repair in a neonate with a large Bochdalek hernia has been reported.<sup>116</sup> The main indication for a laparoscopic approach is a Morgagni hernia which will be addressed in the following section.

## MANAGEMENT OF CDH VARIANTS

### Morgagni hernia

Morgagni hernia is an anterior defect and represents 2% of CDH.<sup>117 118</sup> These patients are usually asymptomatic and often diagnosed later in childhood or even as adults. Laparoscopy is the most common repair approach due to the advantages of a shorter recovery time, less analgesia requirements, better cosmesis and less complications compared with an open repair.<sup>118–120</sup> In contrast, Tan. *et al.* consider a laparotomy particularly useful for very large defects precluding efficient suturing by laparoscopy.<sup>119</sup> Similarly, Karadag *et al.* describe two cases with a very large defect and bleeding due to adherence of the liver to the sac, requiring conversion to open surgery.<sup>121</sup>

Most surgeons prefer defect closure in Morgagni hernia using transabdominal extracorporeally tied interrupted sutures.<sup>117</sup> Patch repair is less common in these patients (13%) and the indication and outcomes are different from patients with Bochdalek-type hernias.<sup>119</sup> Tan *et al.* describe using a patch in most Morgagni hernias, with the exception of small defects.<sup>119</sup> They argue that it reduces the tension on the repair and increases adhesions locally resulting in less recurrences compared with Bochdalek-type hernias.<sup>119 122</sup>

Most Morgagni hernias present with a sac, but there is no consensus on whether or not to resect it.<sup>119</sup> Some authors suggest that leaving the sac increases the recurrence rate or results in fluid accumulation in the residual pouch; others report leaving the sac has no adverse effects.<sup>117 119 121 123 124</sup> Sac excision may allow for better visualization of the posterior defect rim and precise suturing providing a stronger repair.<sup>124</sup> Others argue that resection increases the risk of phrenic nerve, pleural or pericardial injury.<sup>117</sup>

### CDH with hernia sac and eventration

Congenital diaphragmatic eventration is an incompletely muscularized and dysfunctional hemidiaphragm resulting in a contained intrusion of abdominal organs into the thoracic cavity.<sup>125 126</sup> Conversely, a true hernia with a pleuroperitoneal sac occurs in 14%–20% of CDH and is argued to be a variant of ‘classical’ CDH.<sup>126 127</sup> Even though both entities have a different embryological etiology, Heiwegen *et al.* argue them to be part of one clinical spectrum.<sup>126</sup> ‘Classical’ CDH has a lower recurrence rate compared with patients with a hernia sac or eventration.<sup>126</sup> Here, surgeons might underestimate the strength of available diaphragm tissue and choose primary closure or diaphragmatic plication over patch repair. On the other hand, presence of a hernia sac might be associated with smaller defect size (‘A’ and ‘B’). Nonetheless, a lower threshold for patch repair and resection of the sac could potentially reduce the recurrence rate.

## TREATMENT OF RECURRENCE

A large defect, liver-up and patch repair are independent risk factors for recurrence.<sup>24 128</sup> Most recurrences require

surgical repair, but there is no consensus on the best surgical approach.<sup>13</sup>

Traditionally, open surgery was recommended, and muscle flap repairs, as an alternative to a second patch repair, were discussed earlier.<sup>60 64</sup> Most surgeons prefer laparotomy over thoracotomy, however the latter which might be considered in right-sided hernias or in anticipation of significant intra-abdominal adhesions.<sup>129 130</sup> A survey demonstrated that pediatric surgeons who performed initial MIS in left CDH would frequently use the same approach for recurrence.<sup>130</sup> Others suggest a 'virgin tissue plane' using the body cavity opposite to that used for the primary repair has the potential advantage of fewer adhesions and better visibility.<sup>13 130</sup> Recent publications propose MIS for recurrent CDH, regardless of whether a patch was required in the initial repair.<sup>7 129 131 132</sup> Thoracoscopic repair avoids potentially extensive adhesiolysis, especially in large defects, and facilitates repair in patients with gastric or jejunal feeding tubes.<sup>129</sup> Compared with open recurrence surgery, thoracoscopic surgery showed similar operative times, less blood loss and fewer intraoperative complications. There was no added morbidity or risk for subsequent recurrences.<sup>129 131</sup> However, these results are based on retrospective single-institution studies of small heterogenous cohorts over a short follow-up period (2 and 4.7 years).<sup>129 131</sup> Future, multicenter and long-term studies are required to elucidate the indication for MIS in recurrent CDH surgery.

About 19%–25% of cases with recurrent CDH have a second recurrence.<sup>13 129</sup> The adhesiolysis during recurrence surgery potentially increases the fragility of the diaphragmatic remnant and may result in an increased risk for subsequent re-recurrence.<sup>13 131</sup> Tamura *et al.* reported that surgeons with a greater experience in revisional CDH repair have a lower re-recurrence rate.<sup>133</sup> However, the incidence, risk factors and management of subsequent re-recurrences need further investigation.

## FUTURE OUTLOOK

### Robotic surgery

When MIS reaches its limits with regard to visualization and maneuverability, robotic surgery can help. Posterolateral sutures should be securely anchored to prevent recurrence, something that is particularly challenging with rigid instruments. Robotic surgery with articulating instruments could facilitate more precise dissection and intracorporeal suturing. Thoracic robotic surgery is reported in small cohorts and mainly beyond the neonatal age.<sup>134–139</sup> Neonatal thoracic robotic surgery has limitations including available instrument length in relation to patient size, additional costs (extra cost of €500=US\$550/hour for robotic surgery), and lacks evidence for defined patient benefit at this stage.<sup>134 137</sup> However, it opens up opportunities for training future surgeons, planning procedures, and potentially operating at distances away from the patient.<sup>137</sup>

## Tissue and bioengineering

Patches from autologous cells or biodegradable material are investigated as an alternative to prosthetic mesh in treating large diaphragmatic defects. Decellularized diaphragms from mouse,<sup>140</sup> rat,<sup>141 142</sup> pig<sup>143</sup> and human<sup>144</sup> have all been investigated with the aim of developing an autologous biological scaffold with improved diaphragmatic biomechanical function. In an effort to mitigate biohazardous risks of infection and immune reactions, other research focuses on absorbable polymers.<sup>145 146</sup> Bioabsorbable polymer-based patches have been shown to integrate into the muscle<sup>145 146</sup> and contract comparably to native diaphragm,<sup>146</sup> but at the cost of an inflammatory response and adhesions.<sup>145 146</sup> Other challenges in muscle tissue engineering lie in the adequacy of vascularization of these large flaps.<sup>43 142 147</sup> Developments in 3D bioprinting and organoids open new opportunities to develop an optimal patch. One can argue that currently available patch materials provide reasonable options for repair while the mortality and morbidity in CDH are still determined by the lung hypoplasia, and significant advancement in the treatment might come from pulmonary regeneration research.<sup>36 148</sup>

## CONCLUSION

In the surgical treatment of severe CDH, open repair is still the preferred approach. With increased experience and improved techniques, minimally invasive repair has shifted from small to larger defects, but outcomes depend on careful patient selection, surgical technique, surgeon experience and volume of the center. Adherence to standardized reporting of defect size, collection of significant long-term outcome data and large, multicenter studies are required to confirm existing results and develop surgical standards guided by defect size and disease severity.

**Acknowledgements** Susanne Deeg, a consultant at the Department of Pediatric Surgery, University Medical Center Mannheim, created the congenital diaphragmatic hernia image in the center of Figure 1.

**Contributors** MJ: conceptualization, literature review and drafting of the manuscript. RK: conceptualization and revision of the manuscript. MB: review of the manuscript.

**Funding** MJ (519368454) is a holder of the Walter-Benjamin scholarship from the German Research Fund (DFG, Deutsche Forschungsgemeinschaft). RK is the inaugural Thorlakson Chair in Surgical Research for the University of Manitoba.

**Competing interests** None declared.

**Patient consent for publication** Not applicable.

**Ethics approval** Not applicable.

**Provenance and peer review** Commissioned; externally peer reviewed.

**Data availability statement** No data are available.

**Supplemental material** This content has been supplied by the author(s). It has not been vetted by BMJ Publishing Group Limited (BMJ) and may not have been peer-reviewed. Any opinions or recommendations discussed are solely those of the author(s) and are not endorsed by BMJ. BMJ disclaims all liability and responsibility arising from any reliance placed on the content. Where the content includes any translated material, BMJ does not warrant the accuracy and reliability of the translations (including but not limited to local regulations, clinical guidelines,

terminology, drug names and drug dosages), and is not responsible for any error and/or omissions arising from translation and adaptation or otherwise.

**Open access** This is an open access article distributed in accordance with the Creative Commons Attribution Non Commercial (CC BY-NC 4.0) license, which permits others to distribute, remix, adapt, build upon this work non-commercially, and license their derivative works on different terms, provided the original work is properly cited, appropriate credit is given, any changes made indicated, and the use is non-commercial. See: <http://creativecommons.org/licenses/by-nc/4.0/>.

#### ORCID iD

Marietta Jank <http://orcid.org/0000-0002-7064-9687>

#### REFERENCES

- Zani A, Chung WK, Deprest J, et al. Congenital diaphragmatic hernia. *Nat Rev Dis Primers* 2022;8:37.
- Harting MT, Lally KP. The congenital diaphragmatic hernia study group registry update. *Semin Fetal Neonatal Med* 2014;19:370–5.
- Lally KP, Lally PA, Lasky RE, et al. Defect size determines survival in infants with congenital diaphragmatic hernia. *Pediatrics* 2007;120:e651–7.
- Emanuel H, Breitschopf HV, Harting MT, et al. Pulmonary outcomes of congenital diaphragmatic hernia patients based on defect size (CDH study group stage). *Transl Pediatr* 2023;12:1490–503.
- Puligandla P, Skarsgard E, Baird R, et al. Diagnosis and management of congenital diaphragmatic hernia: a 2023 update from the Canadian congenital diaphragmatic hernia collaborative. *Arch Dis Child Fetal Neonatal Ed* 2024;109:239–52.
- Shah NR, Criss CN, Burgi K, et al. Thoracoscopic patch repair of congenital diaphragmatic hernia: can smaller incisions treat larger defects? *J Pediatr Surg* 2024;59:1083–8.
- Keijzer R, van de Ven C, Vlot J, et al. Thoracoscopic repair in congenital diaphragmatic hernia: patching is safe and reduces the recurrence rate. *J Pediatr Surg* 2010;45:953–7.
- Sullivan GA, Skertich NJ, Kwong J, et al. Minimally invasive approaches and use of a patch are not associated with increased recurrence rates after congenital diaphragmatic hernia repair. *J Laparoendosc Adv Surg Tech A* 2022;32:1228–33.
- Putnam LR, Tsao K, Lally KP, et al. Minimally invasive vs open congenital diaphragmatic hernia repair: is there a superior approach? *J Am Coll Surg* 2017;224:416–22.
- Lally KP, Lasky RE, Lally PA, et al. Standardized reporting for congenital diaphragmatic hernia—an international consensus. *J Pediatr Surg* 2013;48:2408–15.
- Levesque M, Derraugh G, Schantz D, et al. The presence of a hernia sac in isolated congenital diaphragmatic hernia is associated with less disease severity: a retrospective cohort study. *J Pediatr Surg* 2019;54:899–902.
- Michel A-J, Metzger U, Rice SA, et al. Thoracoscopic guided pericostal sutures as a solid fixation for primary closure of congenital diaphragmatic hernias. *Children (Basel)* 2022;9:1116.
- Macchini F, Raffaelli G, Amodeo I, et al. Recurrence of congenital diaphragmatic hernia: risk factors, management, and future perspectives. *Front Pediatr* 2022;10:823180.
- Hernandez-Andrade EA, Huntley E, Papanna R, et al. EP29.02: Prediction of large diaphragmatic defects based on prenatal ultrasound findings. *Ultrasound in Obstet Gynecol* 2022;60:212–3.
- Quigley CP, Folaranni SE. A Systematic review comparing the surgical outcomes of open versus minimally invasive surgery for congenital diaphragmatic hernia repair. *J Laparoendosc Adv Surg Tech A* 2023;33:211–9.
- Criss CN, Coughlin MA, Matusko N, et al. Outcomes for thoracoscopic versus open repair of small to moderate congenital diaphragmatic hernias. *J Pediatr Surg* 2018;53:635–9.
- Lansdale N, Alam S, Losty PD, et al. Neonatal endoscopic congenital diaphragmatic hernia repair: a systematic review and meta-analysis. *Ann Surg* 2010;252:20–6.
- Zhu Y, Wu Y, Pu Q, et al. Minimally invasive surgery for congenital diaphragmatic hernia: a meta-analysis. *Hernia* 2016;20:297–302.
- Terui K, Nagata K, Ito M, et al. Surgical approaches for neonatal congenital diaphragmatic hernia: a systematic review and meta-analysis. *Pediatr Surg Int* 2015;31:891–7.
- Yang EY, Allmendinger N, Johnson SM, et al. Neonatal thoracoscopic repair of congenital diaphragmatic hernia: selection criteria for successful outcome. *J Pediatr Surg* 2005;40:1369–75.
- Kim AC, Bryner BS, Akay B, et al. Thoracoscopic repair of congenital diaphragmatic hernia in neonates: lessons learned. *J Laparoendosc Adv Surg Tech A* 2009;19:575–80.
- Cioci AC, Urrechaga EM, Parreco J, et al. One-year outcomes of congenital diaphragmatic hernia repair: factors associated with recurrence and complications. *J Pediatr Surg* 2021;56:1542–6.
- Gomes Ferreira C, Kuhn P, Lacreuse I, et al. Congenital diaphragmatic hernia: an evaluation of risk factors for failure of thoracoscopic primary repair in neonates. *J Pediatr Surg* 2013;48:488–95.
- Putnam LR, Gupta V, Tsao K, et al. Factors associated with early recurrence after congenital diaphragmatic hernia repair. *J Pediatr Surg* 2017;52:928–32.
- Rideout DA, Wulkan M. Thoracoscopic neonatal congenital diaphragmatic hernia repair: how we do it. *J Laparoendosc Adv Surg Tech A* 2021;31:1168–74.
- Vandewalle RJ, Yalcin S, Clifton MS, et al. Biologic mesh underlay in thoracoscopic primary repair of congenital diaphragmatic hernia confers reduced recurrence in neonates: a preliminary report. *J Laparoendosc Adv Surg Tech A* 2019;29:1212–5.
- Chan E, Wayne C, Nasr A. Minimally invasive versus open repair of Bochdalek hernia: a meta-analysis. *J Pediatr Surg* 2014;49:694–9.
- Gander JW, Fisher JC, Gross ER, et al. Early recurrence of congenital diaphragmatic hernia is higher after thoracoscopic than open repair: a single institutional study. *J Pediatr Surg* 2011;46:1303–8.
- Deguchi K, Watanabe M, Yoneyama T, et al. Tension-free thoracoscopic repair of congenital diaphragmatic hernia combined with a percutaneous extracorporeal closure technique: how to do it. *Surg Today* 2023;53:640–6.
- Lishuang M, Yandong W, Shuli L, et al. A comparison of clinical outcomes between endoscopic and open surgery to repair neonatal diaphragmatic hernia. *J Minim Access Surg* 2017;13:182–7.
- Costerus S, Zahn K, van de Ven K, et al. Thoracoscopic versus open repair of CDH in cardiovascular stable neonates. *Surg Endosc* 2016;30:2818–24.
- Jancelewicz T, Langer JC, Chiang M, et al. Thoracoscopic repair of neonatal congenital diaphragmatic hernia (CDH): outcomes after a systematic quality improvement process. *J Pediatr Surg* 2013;48:321–5.
- Kamran A, Zendejas B, Demehri FR, et al. Risk factors for recurrence after thoracoscopic repair of congenital diaphragmatic hernia (CDH). *J Pediatr Surg* 2018;53:2087–91.
- De Bie F, Suply E, Verbelen T, et al. Early surgical complications after congenital diaphragmatic hernia repair by thoracotomy vs. laparotomy: a bicentric comparison. *J Pediatr Surg* 2020;55:2105–10.
- Tsao K, Lally PA, Lally KP, et al. Minimally invasive repair of congenital diaphragmatic hernia. *J Pediatr Surg* 2011;46:1158–64.
- Zani A, Zani-Ruttenstock E, Pierro A. Advances in the surgical approach to congenital diaphragmatic hernia. *Semin Fetal Neonatal Med* 2014;19:364–9.
- Khirallah MG, Elkhadrawy OH, Eldessouki NE, et al. The challenges of the management of the diaphragmatic hernia in children and infants: a retrospective experience of a tertiary hospital. *Ann Pediatr Surg* 2022;18:20.
- Waldhausen JH, Davies L. Pediatric postoperative abdominal wound dehiscence: transverse versus vertical incisions. *J Am Coll Surg* 2000;190:688–91.
- Eeftinck Schattenkerk LD, Musters GD, Nijssen DJ, et al. Incisional hernia after surgical correction of abdominal congenital anomalies in infants: a systematic review with meta-analysis. *Sci Rep* 2020;10:21170.
- Wag K-L, Loff S, Zahn K, et al. Congenital diaphragmatic hernia: a modern day approach. *Semin Pediatr Surg* 2008;17:244–54.
- Eeftinck Schattenkerk LD, Musters GD, Coulter SEL, et al. Incisional hernia after abdominal surgery in infants: a retrospective analysis of incidence and risk factors. *J Pediatr Surg* 2021;56:2107–12.
- Saxena AK, Hayward RK. Patches in Congenital Diaphragmatic Hernia: Systematic Review. *Ann Surg* 2024;280:229–34.
- Saxena AK. Surgical perspectives regarding application of biomaterials for the management of large congenital diaphragmatic hernia defects. *Pediatr Surg Int* 2018;34:475–89.
- Gasior AC, St Peter SD. A review of patch options in the repair of congenital diaphragm defects. *Pediatr Surg Int* 2012;28:327–33.
- Loff S, Wirth H, Jester I, et al. Implantation of a cone-shaped double-fixed patch increases abdominal space and prevents recurrence of large defects in congenital diaphragmatic hernia. *J Pediatr Surg* 2005;40:1701–5.
- Puligandla PS, Grabowski J, Austin M, et al. Management of congenital diaphragmatic hernia: a systematic review from the APSA outcomes and evidence based practice committee. *J Pediatr Surg* 2015;50:1958–70.



- 47 Verla MA, Style CC, Lee TC, *et al.* Does creating a dome reduce recurrence in congenital diaphragmatic hernia following patch repair? *J Pediatr Surg* 2022;57:637–42.
- 48 Ruhrnschopf CG, Reusmann A, Boglione M, *et al.* Biological versus synthetic patch for the repair of congenital diaphragmatic hernia: 8-year experience at a tertiary center. *J Pediatr Surg* 2021;56:1957–61.
- 49 Kamal TR, Tyraskis A, Ghataura H, *et al.* Synthetic versus biological patches for CDH: a comparison of recurrence rates and adverse events, systematic review, and meta-analysis. *Eur J Pediatr Surg* 2023;33:198–209.
- 50 Grethel EJ, Cortes RA, Wagner AJ, *et al.* Prosthetic patches for congenital diaphragmatic hernia repair: Surgisis vs Gore-Tex. *J Pediatr Surg* 2006;41:29–33.
- 51 Romao RLP, Nasr A, Chiu PPL, *et al.* What is the best prosthetic material for patch repair of congenital diaphragmatic hernia? Comparison and meta-analysis of porcine small intestinal submucosa and polytetrafluoroethylene. *J Pediatr Surg* 2012;47:1496–500.
- 52 Jancelewicz T, Vu LT, Keller RL, *et al.* Long-term surgical outcomes in congenital diaphragmatic hernia: observations from a single institution. *J Pediatr Surg* 2010;45:155–60.
- 53 Jancelewicz T, Chiang M, Oliveira C, *et al.* Late surgical outcomes among congenital diaphragmatic hernia (CDH) patients: why long-term follow-up with surgeons is recommended. *J Pediatr Surg* 2013;48:935–41.
- 54 Laituri CA, Garey CL, Valusek PA, *et al.* Outcome of congenital diaphragmatic hernia repair depending on patch type. *Eur J Pediatr Surg* 2010;20:363–5.
- 55 Nasr A, Struijs M-C, Ein SH, *et al.* Outcomes after muscle flap vs prosthetic patch repair for large congenital diaphragmatic hernias. *J Pediatr Surg* 2010;45:151–4.
- 56 Mitchell IC, Garcia NM, Barber R, *et al.* Permacol: a potential biologic patch alternative in congenital diaphragmatic hernia repair. *J Pediatr Surg* 2008;43:2161–4.
- 57 Eastwood MP, Harwood R, Rhodes H, *et al.* Multi-centre prospective cohort study of diaphragmatic defect phenotype and repair in neonates with congenital diaphragmatic hernia: ‘the defect study’. *J Surg Protoc Res Methodol* 2022;2022.
- 58 Zahn KB, Schaible T, Rafat N, *et al.* Longitudinal follow-up with radiologic screening for recurrence and secondary hiatal hernia in neonates with open repair of congenital diaphragmatic hernia—a large prospective, observational cohort study at one referral center. *Front Pediatr* 2021;9:796478.
- 59 Barnhart DC, Jacques E, Scaife ER, *et al.* Split abdominal wall muscle flap repair vs patch repair of large congenital diaphragmatic hernias. *J Pediatr Surg* 2012;47:81–6.
- 60 Sydorak RM, Hoffman W, Lee H, *et al.* Reversed latissimus dorsi muscle flap for repair of recurrent congenital diaphragmatic hernia. *J Pediatr Surg* 2003;38:296–300.
- 61 Samarakkody U, Klaassen M, Nye B. Reconstruction of congenital agenesis of hemidiaphragm by combined reverse latissimus dorsi and serratus anterior muscle flaps. *J Pediatr Surg* 2001;36:1637–40.
- 62 Aydin E, Nolan H, Peiró JL, *et al.* When primary repair is not enough: a comparison of synthetic patch and muscle flap closure in congenital diaphragmatic hernia? *Pediatr Surg Int* 2020;36:485–91.
- 63 Nolan H, Aydin E, Frischer JS, *et al.* Hemorrhage after on-ECMO repair of CDH is equivalent for muscle flap and prosthetic patch. *J Pediatr Surg* 2019;54:2044–7.
- 64 Masumoto K, Nagata K, Souzaki R, *et al.* Effectiveness of diaphragmatic repair using an abdominal muscle flap in patients with recurrent congenital diaphragmatic hernia. *J Pediatr Surg* 2007;42:2007–11.
- 65 Brant-Zawadzki PB, Fenton SJ, Nichol PF, *et al.* The split abdominal wall muscle flap repair for large congenital diaphragmatic hernias on extracorporeal membrane oxygenation. *J Pediatr Surg* 2007;42:1047–51.
- 66 Molino JA, García Martínez L, Guillén Burrieza G, *et al.* Outcomes after split abdominal wall muscle flap repair for large congenital diaphragmatic hernias. *Eur J Pediatr Surg* 2020;30:210–4.
- 67 Joshi SB, Sen S, Chacko J, *et al.* Abdominal muscle flap repair for large defects of the diaphragm. *Ped Surg Int* 2005;21:677–80.
- 68 Bianchi A, Doig CM, Cohen SJ. The reverse latissimus dorsi flap for congenital diaphragmatic hernia repair. *J Pediatr Surg* 1983;18:560–3.
- 69 MEEKER IA Jr, SNYDER WH Jr. Surgical management of diaphragmatic defects in the newborn infant. a report of twenty infants each less than one week old (1956–1961). *Am J Surg* 1962;104:196–203.
- 70 Russell KW, Barnhart DC, Rollins MD, *et al.* Musculoskeletal deformities following repair of large congenital diaphragmatic hernias. *J Pediatr Surg* 2014;49:886–9.
- 71 Dewberry L, Hilton S, Gien J, *et al.* Flap repair in congenital diaphragmatic hernia leads to lower rates of recurrence. *J Pediatr Surg* 2019;54:2487–91.
- 72 Lee SL, Poulos ND, Greenholz SK. Staged reconstruction of large congenital diaphragmatic defects with synthetic patch followed by reverse latissimus dorsi muscle. *J Pediatr Surg* 2002;37:367–70.
- 73 Okazaki T, Hasegawa S, Urushihara N, *et al.* Toldt’s fascia flap: a new technique for repairing large diaphragmatic hernias. *Ped Surg Int* 2005;21:64–7.
- 74 Guglielmetti LC, Estrada AE, Phillips R, *et al.* Congenital diaphragmatic hernias: severe defect grade predicts the need for fundoplication. *Medicine (Baltimore)* 2020;99:e23383.
- 75 von Schrottenberg C, Deeg S, Weiss C, *et al.* Long-term evaluation of gastroesophageal reflux in neonates with and without preventive anti-reflux surgery at the time of congenital diaphragmatic hernia repair. *Children (Basel)* 2022;9:1137.
- 76 Montalvo L, Carricaburu E, Sfeir R, *et al.* Anti-reflux surgery in children with congenital diaphragmatic hernia: a prospective cohort study on a controversial practice. *J Pediatr Surg* 2022;57:826–33.
- 77 Maxwell D, Baird R, Puligandla P. Abdominal wall closure in neonates after congenital diaphragmatic hernia repair. *J Pediatr Surg* 2013;48:930–4.
- 78 Hiradfar M, Shojaeian R, Gharavi Fard M. Two-stage endoscopic repair of congenital diaphragmatic hernia. *BMJ Case Rep* 2016;2016:10.
- 79 Bogusz B, Mol A, Zgraj O, *et al.* The application of the percutaneous suturing technique in thoracoscopic repair of congenital diaphragmatic hernia. *Adv Clin Exp Med* 2020;29:967–70.
- 80 Mortellaro VE, Fike FB, Adibe OO, *et al.* The use of high-frequency oscillating ventilation to facilitate stability during neonatal thoracoscopic operations. *J Laparoendosc Adv Surg Tech* 2011;21:877–9.
- 81 Budzanowski A, Loukogeorgakis S, Mullassery D, *et al.* Thoracoscopic vs open repair of congenital diaphragmatic hernia after extracorporeal membrane oxygenation: a comparison of intra-operative data. *Pediatr Surg Int* 2023;39:82.
- 82 Schlager A, Arps K, Siddharthan R, *et al.* Thoracoscopic repair of congenital diaphragmatic hernia after extracorporeal membrane oxygenation: feasibility and outcomes. *J Laparoendosc Adv Surg Tech A* 2018;28:774–9.
- 83 Cho SD, Krishnaswami S, Mckee JC, *et al.* Analysis of 29 consecutive thoracoscopic repairs of congenital diaphragmatic hernia in neonates compared to historical controls. *J Pediatr Surg* 2009;44:80–6.
- 84 Lukish J, Rasmussen S, Garrett D, *et al.* Utilization of a novel unidirectional knottless suture during minimal access procedures in pediatric surgery. *J Pediatr Surg* 2013;48:1445–9.
- 85 Burgmeier C, Schier F. Hemodynamic effects of thoracoscopic surgery in neonates with cardiac anomalies. *J Laparoendosc Adv Surg Tech A* 2014;24:265–7.
- 86 Mansour S, Curry J, Blackburn S, *et al.* Minimal access surgery for congenital diaphragmatic hernia: surgical tricks to facilitate anchoring the patches to the ribs. *Pediatr Surg Int* 2023;39:135.
- 87 Okawada M, Ohfuji S, Yamoto M, *et al.* Thoracoscopic repair of congenital diaphragmatic hernia in neonates: findings of a multicenter study in Japan. *Surg Today* 2021;51:1694–702.
- 88 Nam SH, Cho MJ, Kim DY, *et al.* Shifting from laparotomy to thoracoscopic repair of congenital diaphragmatic hernia in neonates: early experience. *World J Surg* 2013;37:2711–6.
- 89 Long A-M, Bunch KJ, Knight M, *et al.* One-year outcomes of infants born with congenital diaphragmatic hernia: a national population cohort study. *Arch Dis Child Fetal Neonatal Ed* 2019;104:F643–7.
- 90 Zahn KB, Franz A-M, Schaible T, *et al.* Small bowel obstruction after neonatal repair of congenital diaphragmatic hernia—incidence and risk-factors identified in a large longitudinal cohort-study. *Front Pediatr* 2022;10:846630.
- 91 Inoue M, Uchida K, Otake K, *et al.* Thoracoscopic repair of congenital diaphragmatic hernia with countermeasures against reported complications for safe outcomes comparable to laparotomy. *Surg Endosc* 2016;30:1014–9.
- 92 Li H, Zhao S, Wu C, *et al.* A new simplified technique in thoracoscopic repair of congenital diaphragmatic hernia. *Pediatr Surg Int* 2022;38:861–5.
- 93 Al-Jazaeri A. Simplified technique for minimally invasive repair of congenital diaphragmatic hernia using hollow-needle snare and transthoracic traction stitches. *J Pediatr Surg* 2012;47:258–63.

- 94 Li B, Li S-T, Chen W-B, *et al.* Thoracoscopic repair by simplified mattress sutures for diaphragmatic hernia in the neonate when no posterolateral diaphragmatic rim exists. *J Laparoendosc Adv Surg Tech* 2019;29:710–3.
- 95 Poupalou A, Vrancken C, Vanderveken E, *et al.* Use of nonabsorbable spiral tacks for mesh reinforcement in thoracoscopic repair of congenital diaphragmatic hernia. *European J Pediatr Surg Rep* 2018;6:e27–31.
- 96 Li B, Chen BW, Wang QS, *et al.* Thoracoscopic repair of diaphragmatic hernia in infants: a new modification of the technique. *Eur J Pediatr Surg* 2016;26:519–23.
- 97 He Q, Zhong W, Wang Z, *et al.* Simple and safe thoracoscopic repair of neonatal congenital diaphragmatic hernia by a new modified knot-tying technique. *Hernia* 2019;23:1275–8.
- 98 Chen C, Zeng Q, Zhang N, *et al.* Application of an extracorporeal-assisted intracorporeal sliding knot-tying technique in minimally invasive surgery in children. *J Laparoendosc Adv Surg Tech* 2019;29:1197–200.
- 99 Rozmiarek A, Weinsheimer R, Azzie G. Primary thoracoscopic repair of diaphragmatic hernia with pericostal sutures. *J Laparoendosc Adv Surg Tech* 2005;15:667–9.
- 100 McBride CA, Patel B. Letter to the editor. *J Pediatr Surg* 2012;47:1629–30.
- 101 Abello C, Varela MF, Oria M, *et al.* Innovative, stabilizing self-expandable patch for easier and safer thoracoscopic repair of congenital diaphragmatic hernia. *J Laparoendosc Adv Surg Tech A* 2020;30:1242–7.
- 102 Fukuzawa H, Tamaki A, Takemoto J, *et al.* Thoracoscopic repair of a large neonatal congenital diaphragmatic hernia using gerota's fascia. *Asian J Endosc Surgery* 2015;8:219–22.
- 103 Wagner R, Mayer S, Feng X, *et al.* Thoracoscopic repair of congenital diaphragmatic hernia. *Eur J Pediatr Surg* 2020;30:137–41.
- 104 Qin J, Ren Y, Ma D. A comparative study of thoracoscopic and open surgery of congenital diaphragmatic hernia in neonates. *J Cardiothorac Surg* 2019;14:118.
- 105 Zani A, Lamas-Pinheiro R, Paraboschi I, *et al.* Intraoperative acidosis and hypercapnia during thoracoscopic repair of congenital diaphragmatic hernia and esophageal atresia/tracheoesophageal fistula. *Paediatr Anaesth* 2017;27:841–8.
- 106 Bliss D, Matar M, Krishnaswami S. Should intraoperative hypercapnea or hypercarbia raise concern in neonates undergoing thoracoscopic repair of diaphragmatic hernia of bochdalek? *J Laparoendosc Adv Surg Tech* 2009;19:s55–8.
- 107 McHoney M, Giacomello L, Nah SA, *et al.* Thoracoscopic repair of congenital diaphragmatic hernia: intraoperative ventilation and recurrence. *J Pediatr Surg* 2010;45:355–9.
- 108 Liu H, Le C, Chen J, *et al.* Anesthetic management of thoracoscopic procedures in neonates: a retrospective analysis of 45 cases. *Transl Pediatr* 2021;10:2035–43.
- 109 Bishay M, Giacomello L, Retrosi G, *et al.* Decreased cerebral oxygen saturation during thoracoscopic repair of congenital diaphragmatic hernia and esophageal atresia in infants. *J Pediatr Surg* 2011;46:47–51.
- 110 Bishay M, Giacomello L, Retrosi G, *et al.* Hypercapnia and acidosis during open and thoracoscopic repair of congenital diaphragmatic hernia and esophageal atresia: results of a pilot randomized controlled trial. *Ann Surg* 2013;258:895.
- 111 Szavay PO, Obermayr F, Maas C, *et al.* Perioperative outcome of patients with congenital diaphragmatic hernia undergoing open versus minimally invasive surgery. *J Laparoendosc Adv Surg Tech* 2012;22:285–9.
- 112 Okazaki T, Okawada M, Koga H, *et al.* Safety of surgery for neonatal congenital diaphragmatic hernia as reflected by arterial blood gas monitoring: thoracoscopic versus open repair. *Pediatr Surg Int* 2015;31:899–904.
- 113 Costerus S, Vlot J, van Rosmalen J, *et al.* Effects of neonatal thoracoscopic surgery on tissue oxygenation: a pilot study on (neuro-) monitoring and outcomes. *Eur J Pediatr Surg* 2019;29:166–72.
- 114 Lacher M, St Peter SD, Laje P, *et al.* Thoracoscopic CDH Repair—a survey on opinion and experience among IPEG members. *J Laparoendosc Adv Surg Tech* 2015;25:954–7.
- 115 Style CC, Olutoye OO, Belfort MA, *et al.* Fetal endoscopic tracheal occlusion reduces pulmonary hypertension in severe congenital diaphragmatic hernia. *Ultrasound Obstet Gynecol* 2019;54:752–8.
- 116 Holcomb GW, Ostlie DJ, Miller KA. Laparoscopic patch repair of diaphragmatic hernias with surgisis. *J Pediatr Surg* 2005;40:e1–5.
- 117 Alqadi G, Saxena AK. Laparoscopic morgagni hernia repair in children: systematic review. *J Ped Endosc Surg* 2019;1:85–90.
- 118 Laituri CA, Garey CL, Ostlie DJ, *et al.* Morgagni hernia repair in children: comparison of laparoscopic and open results. *J Laparoendosc Adv Surg Tech* 2011;21:89–91.
- 119 Tan Y-W, Banerjee D, Cross KM, *et al.* Morgagni hernia repair in children over two decades: institutional experience, systematic review, and meta-analysis of 296 patients. *J Pediatr Surg* 2018;53:1883–9.
- 120 Al-Salem AH, Zamakhshary M, Al Mohaidly M, *et al.* Congenital morgagni's hernia: a national multicenter study. *J Pediatr Surg* 2014;49:503–7.
- 121 Karadag CA, Erginel B, Yildiz A, *et al.* Laparoscopic repair of morgagni hernia in children. *J Pediatr Surg* 2023;58:1670–3.
- 122 Dutta S, Albanese CT. Use of a prosthetic patch for laparoscopic repair of morgagni diaphragmatic hernia in children. *J Laparoendosc Adv Surg Tech A* 2007;17:391–4.
- 123 Alqahtani A, Al-Salem AH. Laparoscopic-assisted versus open repair of morgagni hernia in infants and children. *Surg Laparosc Endosc Percutan Tech* 2011;21:46–9.
- 124 Ergun E, Gollu G, Ates U, *et al.* Laparoscopic assisted anterior transabdominal wall closure using loop suture removing technique in morgagni hernia: safe and easy method. *Pediatr Surg Int* 2020;36:679–85.
- 125 Yazici M, Karaca I, Arikana A, *et al.* Congenital eventration of the diaphragm in children: 25 years' experience in three pediatric surgery centers. *Eur J Pediatr Surg* 2003;13:298–301.
- 126 Heiwegen K, van Heijst AF, Daniels-Scharbatke H, *et al.* Congenital diaphragmatic eventration and hernia sac compared to CDH with true defects: a retrospective cohort study. *Eur J Pediatr* 2020;179:855–63.
- 127 Raitio A, Salim A, Losty PD. Congenital diaphragmatic hernia—does the presence of a hernia sac improve outcome? A systematic review of published studies. *Eur J Pediatr* 2021;180:333–7.
- 128 Heiwegen K, de Blaauw I, Botden S. A systematic review and meta-analysis of surgical morbidity of primary versus patch repaired congenital diaphragmatic hernia patients. *Sci Rep* 2021;11:12661.
- 129 Kunisaki SM, Powelson IA, Bruch SW, *et al.* Thoracoscopic repair of recurrent bochdalek diaphragmatic hernias in children. *J Laparoendosc Adv Surg Tech A* 2012;22:1004–9.
- 130 Bruns NE, Glenn IC, McNinch NL, *et al.* Approach to recurrent congenital diaphragmatic hernia: results of an international survey. *J Laparoendosc Adv Surg Tech* 2016;26:925–9.
- 131 Gohda Y, Yokota K, Uchida H, *et al.* Safe thoracoscopic repair of recurrent congenital diaphragmatic hernia after initial open abdominal repair. *Surg Today* 2024;54:534–9.
- 132 Liu R, Zheng Z, Tang C, *et al.* Thoracoscopic surgery for congenital diaphragmatic hernia in neonates: should it be the first choice? *Front Pediatr* 2022;10:1020062.
- 133 Tamura R, O'Connor E, Jaffray B. Surgeon level variation in outcome of repair of congenital diaphragmatic hernia with particular reference to the management of recurrence. *J Pediatr Surg* 2021;56:2207–14.
- 134 Ballouhey Q, Villemagne T, Cros J, *et al.* Assessment of paediatric thoracic robotic surgery. *Interact Cardiovasc Thorac Surg* 2015;20:300–3.
- 135 Slater BJ, Meehan JJ. Robotic repair of congenital diaphragmatic anomalies. *J Laparoendosc Adv Surg Tech* 2009;19:s123–7.
- 136 Meehan JJ, Sandler A. Robotic repair of a bochdalek congenital diaphragmatic hernia in a small neonate: robotic advantages and limitations. *J Pediatr Surg* 2007;42:1757–60.
- 137 Klein MD, Langenburg SE, Kabeer M, *et al.* Pediatric robotic surgery: lessons from a clinical experience. *J Laparoendosc Adv Surg Tech* 2007;17:265–71.
- 138 Alqahtani A, Albassam A, Zamakhshary M, *et al.* Robot-assisted pediatric surgery: how far can we go? *World J Surg* 2010;34:975–8.
- 139 Anderberg M, Clementson Kockum C, Arnbjornsson E. Morgagni hernia repair in a small child using da vinci robotic instruments – a case report. *Eur J Pediatr Surg* 2009;19:110–2.
- 140 Trevisan C, Maghin E, Dedja A, *et al.* Allogenic tissue-specific decellularized scaffolds promote long-term muscle innervation and functional recovery in a surgical diaphragmatic hernia model. *Acta Biomater* 2019;89:115–25.
- 141 Liao GP, Choi Y, Vojnits K, *et al.* Tissue engineering to repair diaphragmatic defect in a rat model. *Stem Cells Int* 2017;2017:1764523.
- 142 Conconi MT, Bellini S, Teoli D, *et al.* In vitro and in vivo evaluation of acellular diaphragmatic matrices seeded with muscle precursor cells and coated with VEGF silica gels to repair muscle defect of the diaphragm. *J Biomed Mater Res* 2009;89A:304–16.

- 143 Boso D, Carraro E, Maghin E, *et al.* Porcine decellularized diaphragm hydrogel: a new option for skeletal muscle malformations. *Biomedicines* 2021;9:709.
- 144 Barbon S, Stocco E, Contran M, *et al.* Preclinical development of bioengineered allografts derived from decellularized human diaphragm. *Biomedicines* 2022;10:739.
- 145 Aikawa M, Miyazawa M, Okamoto K, *et al.* A newly designed bioabsorbable substitute for the treatment of diaphragmatic defects. *Surg Today* 2013;43:1298–304.
- 146 Theodorou CM, Taylor A, Lee SY, *et al.* Evaluation of a biodegradable polyurethane patch for repair of diaphragmatic hernia in a rat model: a pilot study. *J Pediatr Surg* 2023;58:964–70.
- 147 Alvarèz Fallas ME, Piccoli M, Franzin C, *et al.* Decellularized diaphragmatic muscle drives a constructive angiogenic response in vivo. *Int J Mol Sci* 2018;19:1319.
- 148 Garriboli M, Eaton S, Pierro A, *et al.* More patches or more lung in congenital diaphragmatic hernia? *J Pediatr Surg* 2012;47:1968–9.