World Journal of Pediatric Surgery

Use of a neoprene binding to reduce giant omphaloceles followed by delayed closure

Barbara Lelj-Garolla ,[1,2] Lorena Campbell,[2] Jaideep Kanungo,[1,2] Naomi Yoshida[3,4]

To cite: Lelj-Garolla B, Campbell L, Kanungo J, *et al*. Use of a neoprene binding to reduce giant omphaloceles followed by delayed closure. *World Jnl Ped Surgery* 2021;**4**:e000284. doi:10.1136/wjps-2021-000284

► Additional supplemental material is published online only. To view, please visit the journal online (http://dx.doi.org/10.1136/wjps-2021-000284).

Received 1 April 2021
Accepted 2 September 2021

[1]Department of Paediatrics, The University of British Columbia Faculty of Medicine, Vancouver, British Columbia, Canada
[2]Department of Paediatrics, Victoria General Hospital, Victoria, British Columbia, Canada
[3]Department of General Surgery, The University of British Columbia Faculty of Medicine, Vancouver, British Columbia, Canada
[4]Department of General Surgery, Victoria General Hospital, Victoria, British Columbia, Canada

Correspondence to
Dr Barbara Lelj-Garolla; blelj@alumni.ubc.ca

Omphaloceles occur in about 1 in 5000 births and are the second most common congenital abdominal wall defects.[1] Repair remains a surgeon's preference with early closure only attempted for small-to-medium omphaloceles, while delayed closure is used for giant omphaloceles.[2–4] In recent years, novel techniques that aim at reducing the disproportion between the abdominal cavity and the volume of the extra-abdominal viscera have been described to manage giant omphaloceles.[4–17]

Although less commonly associated with genetic abnormalities, giant omphaloceles are associated with adverse neurodevelopmental outcome at 2 years.[18] In addition to gestational age, birth weight, associated malformation, resuscitation and hypoxia, other factors including prolonged stay in the neonatal intensive care unit (NICU), time on ventilation, infections, and delayed establishment of enteral nutrition are likely contributory factors.[19]

This is a case study of two infants with giant omphaloceles treated in our institution with a novel neoprene binder preoperatively. The binder allows for gradual reduction of the viscera below the level of the skin followed by early fascia closure. Families were contacted for a follow-up survey about parental experience and satisfaction in March–July 2020. A summary of the demographic and outcomes is reported in table 1.

Both infants had giant omphaloceles[2 3] larger than 5 cm with most of the liver and bowel in the sac. Neither had other major abnormalities nor genetic disorders. After delivery, infants were wrapped in a plastic bag to protect the omphalocele sac and were transferred to NICU for initial care. Infants did not require sedation or intubation, and enteral feeds were started on day 1 of life, with 5 and 11 days, respectively, of concomitant parenteral nutrition until full enteral feeds were established. Immediately postnatally, the intact sac was cleaned and dressed with Restore silver dressing and was wrapped with kling gauze. The neoprene silo binders were custom built by our NICU occupational therapists (guide in online supplemental appendix 1) and were customized based on omphalocele, abdominal opening and baby sizes (figure 1, online supplemental table 1, online supplemental figures 1–6). Compression began on the first day of life. All the changes to compression were done with the infant awake—no sedation, paralysis or analgesic other than occasional sugar water was used (online supplemental figure 1). Parents were able to hold their babies from day 2 of life.

The binder includes three components (figure 1 and online supplemental figures 1–3). The first component (piece 1) is a full torso wrap with Velcro closure and a hole cut to the circumference of the omphalocele. The second component is a neoprene silo attached to the torso wrap (pieces 2+3). The height of this silo starts 1–2 cm below the total height of the dressed and contained omphalocele. During application, care is made to prevent a 'mushrooming' effect of the omphalocele over the top of the silo to prevent the defect from getting wider. The third component (piece 4) is a compression strap that is placed over top of the silo with wide straps extending down to the torso wrap (figures 2 and 3A,B). Suspended external devices were not necessary because the neoprene offers enough rigidity to hold the silo upright. Minor readjustments—tightening of the compression and silo circumference straps, as well as adding gauze inside the silo to aid in downward compression (figure 3C)—were made once or twice per day. Restore silver dressing was used daily on non-epithelialized areas until skin was full epithelialized and then was discontinued. Infant response was assessed clinically without invasive monitoring. When the omphalocele was close to the level of the

Table 1 Summary of patient's demographic and outcomes

	Patient 1	Patient 2
Birth weight (g)	2680	2441
Gestational age at birth (wk+d)	37+4	36+0
Comorbidities	Small muscular VSD and small ASD secundum	Twin pregnancy/IUGR ASD/PFO
Type of omphalocele	Giant omphalocele with liver and most of the bowels in the sac	Giant omphalocele with liver and most of the bowels in the sac
APGAR scores	8, 9, 10	7, 8, 9
Respiratory support (excluded intraoperative support)	None	None
Days sedated (excluded intraoperative sedation)	None	None
Age when enteral feeds were started (d)	1	1
Number of days of exclusive parenteral nutrition	0	0
Days of life on parenteral nutrition	1–5	1–11
Age when held by parents after binder applied (d)	2	2
Age at time of surgery (d)	47	102
Age at time of discharge (d)	59	113
Need for patch	No	No
Nursing concerns	Occasional superficial abrasion of the skin with bindings	Occasional concerns about binding tightness causing leg discoloration or tachypnea

APGAR, Appearance, Pulse, Grimace, Activity, Respiration; ASD, atrial septal defect; IUGR, intrauterine growth restriction; PFO, patent foramen ovale; VSD, ventricular septal defect.



Figure 1 Components of the omphalocele binder. (A) Torso wrap with hole cut to fit over omphalocele. (B,C) These two parts will make the silo to support the omphalocele. (D) The compression strap that will fit over the top of the silo. Please refer to guide in online supplemental appendix 1 for all the details and how to measure infants to make a binder to fit each infant. Asterisks indicate the area narrowed to accommodate the shoulder blades. r, diameter of whole in torso wrap; s, width of compression band (piece 4)=20% wider than the diameter of the hole in the torso wrap r; t, length of the compression band (piece 4)=4.5 times the height of the omphalocele (x); u, length of piece 2 equivalent to half the circumference of the neck of the omphalocele; v, length of piece 3 which is 20%–30% longer than piece 2; w, torso length; x, the height of the omphalocele when the peritoneal sac is gently contained to extend upright within the circumference of the abdominal wall defect from base to top; y, the circumference of the infant's torso plus 10%–15% for overlap and growth; z, the circumference of the abdominal wall defect.

abdominal wall, a foam disk 'plunger' (figure 3D) was added inside the silo under the compression strap, this allowed compression while at the same time preventing 'mushrooming'. This 'plunger' provided sufficient compression to invert the omphalocele in preparation for surgery (figure 3D). As the omphalocele decreased in size and the infant became more active, straps over the shoulders and the diaper were used to keep compression centered over the abdominal opening (figure 3B and online supplemental figure 6). Major readjustments were made every 2–4 days by cutting down the silos' height and by adjusting the torso wrap and the compression strap for the changing shape of the omphalocele. A key feature of our technique is that it allows the liver and hepatic vessels to move back into the abdominal cavity gradually, as the abdominal space naturally increases, reducing the risk of hepatic vessels kinking and reducing the potential damage to the liver. In addition, our infants remained stable from a cardiorespiratory point of view, did not develop pulmonary hypertension, and did not require any respiratory support. Figure 4 shows a progression of the omphalocele reduction in the abdominal cavity.

When the abdominal content was completely reduced below the fascia, the babies were brought to the operating room for primary surgical repair. At the time of surgery, both babies had fully reducible omphaloceles with enough growth of fascia and skin to allow primary closure without the need of a patch. One child had enough excess skin available to create a pseudo umbilicus (figure 4). Both patients had closure of the muscle layers at the time of surgery. Airway pressures, urine output and lower limb perfusion were monitored throughout the surgical procedure for respiratory compromise and abdominal compartment symptom.

Babies were extubated in the operating room and were brought back to NICU for postoperative care. This included wound and pain management and resumption of enteral feeds when bowel sounds were present. During the postoperative period, infants were awake, they did not require muscle relaxant or any invasive monitoring. Time to surgery was 47 days (baby 1) and 102 days (baby 2), and both infants were discharged 12 days postoperatively.

Neither patients had further surgical needs, hospital readmission or complications from surgery in the first 2 and 4 years of life, respectively. Overall complications



Figure 2 Assembly of the omphalocele binder. (A,B) Depict use of a standard sewing machine to sew flat edges of the silo piece (2) to the hole in the torso wrap (1) using zigzag stitch, piece 3 is sewn in a similar manner; (C) depicts the beveled edge cut into the inner component of the silo to reduce pressure ridges; (D) depicts the three-dimensional shapes created by these flat zigzag stitched seams for both the silo and the compression band. Note that the torso wrap has been cut to have reduced width around the shoulder blade. (E) Shows the assembled binder with Velcro closures that can be used to increase or decrease compression of the omphalocele to support gradual reduction into the abdominal cavity.

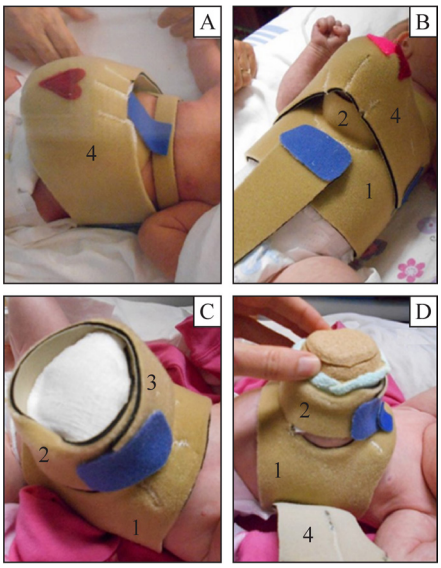

Figure 3 Neoprene omphalocele binder in use. (A) Early days of wearing the binder. (B) Strap added over diaper (and shoulders) to hold the torso wrap in place and maintain omphalocele over top of the abdominal opening. (C) The silo has been cut down significantly from the initial version and gauze has aided in the compression of the omphalocele within the silo. (D) A foam plunger used inside the silo increases the downward compression of the omphalocele contents to take advantage of the increased intra-abdominal space. 1, torso wrap; 2 and 3, silo components; 4, compression strap.

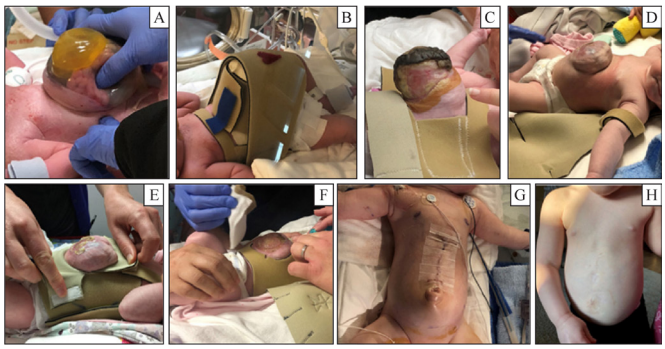

Figure 4 Progression of omphalocele reduction. (A) Immediately postnatally; (B) Initial binder; (C–F) Progressive reduction of omphaloceles; (G) Immediately postoperatively; (H) Child at age 4.

included skin breakdown, suture reaction, and small abscesses post-surgery that did not require antibiotics.

A follow-up survey (online supplemental appendix 2) was sent to parents to assess parental satisfaction and their expectations preoperatively and postoperatively. Caregivers had incredibly positive views of the binder, the surgery, and the outcome (table 2). Neither babies had any developmental issues at age 2 and 4 years, respectively.

Techniques that use compression to reduce omphaloceles within the abdominal cavity prior to surgery aim at increasing available skin and fascia to obtain primary closure, ideally without the use of a patch.[4–16] In addition to those aims, our goals also included avoiding repeat surgeries, reducing developing brain's exposure to sedative and analgesic medications, early enteral feeds, and allowing for normal infant neurodevelopment. Our technique is easy to reproduce and customize with low-cost neoprene and a sewing machine. The binder is easily applied, adjusted and removed, reducing the risk of increased intrathoracic pressure, pulmonary hypertension, compression of vena cava, limb ischemia, respiratory distress, and skin break down. Children were awake, not paralyzed, and were able to do early tummy time. Early enteral feeds were achieved, which removed the need for long-term intravenous access. No pain was associated with the application of the binder, and there were minimal nursing concerns. Our survey showed that both families had negative expectation of outcome when the diagnosis of omphalocele was made prenatally, but are currently doing well, with minimal impact to the child and are developmentally on par with children of similar age.

One consideration with our technique is the need for hospitalization until time of surgery. Given that the omphalocele is not reduced in the abdominal cavity immediately, we felt it was safer for the children to remain in hospital for monitoring. Infants had early transfers to our level II NICU and only require 2–3 days of admission in level III NICU—immediately postnatally and immediately post-surgically. Infants have not required any other time in hospital since the time of discharge. In addition, families have not required other interventions (occupational

Table 2 Summary of results from parent's survey

Survey question	Patient 1	Patient 2
What is your relationship to the child that underwent omphalocele repair?	Grandmother and mother filled the survey together as both are involved with raising the child	Mother
Prior to the surgery, what expectations did you have in regard to outcome?	Death while pregnant. Shortly after birth, a difficult postoperative recovery with many long term-complications	Death (while pregnant)
Are you satisfied with the surgery? (0=no; 10=completely satisfied)	10	10
How did the overall outcome compare with your expectation prior to surgery? (0=worse; 10=better)	10	10
How do you think your child is doing now? (1: not very well; 10: very well)	10	8.5
Has having an omphalocele negatively affected your child's quality of life? (1: very much; 10: not at all)	9	8.5
Has having an omphalocele negatively affected your quality of life? (1: very much; 10: not at all)	8	8
Qualitative comments	*'[My child] is a very active toddler.'* *'[My child] is just as active as the other children and is not bothered at all by the scar, as a caregiver I am more concerned and sometime slow [my baby] down out of fear.'* *'[My child] eats less food/drink at the time' and 'friends commenting negatively on the tummy scar.'* *'We are very thankful to Dr [surgeon] and Victoria General hospital for the loving care.'*	*'[My child] is just as vivacious and curious as any other toddler, outpaces the 6-year-old brother and has physically exceeded the twin since 6 month of age.'* *'It took less time for the omphalocele to go down than expected.'*

therapy, physiotherapy, education support, etc) which, in the lifetime of the child, would reduce the burden to the healthcare system, the insurance companies or the family in a privately paying system.

It is evident that many surgical groups around the world have noted the value of reducing the size of omphalocele prior to surgery, and others have used a neoprene binder in gynecological surgeries with positive outcomes.[20] We believe that broad adoption of a neoprene binder can increase the success of the repair and can improve developmental outcome of children with giant omphaloceles.

Acknowledgements Thank you to the families who participated in our study. We would also like to thank Dr Scott Cameron for critical appraisal of our manuscripts.

Contributors BL-G contributed to conceptualization, formal analysis, visualization, investigation, writing original draft and guarantor. LC contributed to visualization and writing original draft. JK contributed to conceptualization and writing review and editing. NY contributed to conceptualization and writing review and editing. SC contributed to writing review and editing.

Funding The authors have not declared a specific grant for this research from any funding agency in the public, commercial or not-for-profit sectors.

Competing interests None declared.

Patient consent for publication Parental/guardian consent obtained.

Ethics approval Ethical approval was obtained from the Health Research Ethics Board (HREB) (study # H2019-076) for the retrospective study and the qualitative study of parent's satisfaction level.

Provenance and peer review Not commissioned; externally peer reviewed.

Data availability statement All data relevant to the study are included in the article or uploaded as supplemental information. All relevant data are available in the manuscript. A detailed guide on how to build the neoprene silos has been added as supplemental material in the hope of disseminating the information widely and allowing other surgical team to easily reproduce it.

ORCID iD
Barbara Lelj-Garolla http://orcid.org/0000-0002-6436-3850

REFERENCES

1 Radhakrishna U, Nath SK, McElreavey K, *et al*. Genome-wide linkage and copy number variation analysis reveals 710 KB duplication on chromosome 1p31.3 responsible for autosomal dominant omphalocele. *J Med Genet* 2012;49:270–6.
2 Biard J-M, Wilson RD, Johnson MP, *et al*. Prenatally diagnosed giant omphaloceles: short- and long-term outcomes. *Prenat Diagn* 2004;24:434–9.
3 Tucci M, Bard H. The associated anomalies that determine prognosis in congenital omphaloceles. *Am J Obstet Gynecol* 1990;163:1646–9.
4 Bauman B, Stephens D, Gershone H, *et al*. Management of giant omphaloceles: a systematic review of methods of staged surgical vs. nonoperative delayed closure. *J Pediatr Surg* 2016;51:1725–30.
5 Nuchtern JG, Baxter R, Hatch EI. Nonoperative initial management versus silon chimney for treatment of giant omphalocele. *J Pediatr Surg* 1995;30:771–6.
6 Brown MF, Wright L. Delayed external compression reduction of an omphalocele (DECRO): an alternative method of treatment for moderate and large omphaloceles. *J Pediatr Surg* 1998;33:1113–6.
7 Hendrickson RJ, Partrick DA, Janik JS. Management of giant omphalocele in a premature low-birth-weight neonate utilizing a bedside sequential clamping technique without prosthesis. *J Pediatr Surg* 2003;38:E14–16.
8 Foglia R, Kane A, Becker D, *et al*. Management of giant omphalocele with rapid creation of abdominal domain. *J Pediatr Surg* 2006;41:704–9.
9 Alaish SM, Strauch ED. The use of alloderm in the closure of a giant omphalocele. *J Pediatr Surg* 2006;41:e37–9.
10 Kilbride KE, Cooney DR, Custer MD. Vacuum-assisted closure: a new method for treating patients with giant omphalocele. *J Pediatr Surg* 2006;41:212–5.
11 Gupta P. Innovative and cost-effective management of large omphalocele. *J Pediatr Surg* 2007;42:1130–2.

12 Baird R, Gholoum S, Laberge J-M, *et al*. Management of a giant omphalocele with an external skin closure system. *J Pediatr Surg* 2010;45:e17–20.
13 Sheth NP. "The use of intraabdominal tissue expanders as a primary strategy for closure of giant omphalocele" by Drs Martin, Khan, Kim et al. *J Pediatr Surg* 2010;45:1384.
14 van Eijck FC, Aronson DA, Hoogeveen YL, *et al*. Past and current surgical treatment of giant omphalocele: outcome of a questionnaire sent to authors. *J Pediatr Surg* 2011;46:482–8.
15 Aldridge B, Ladd AP, Kepple J, *et al*. Negative pressure wound therapy for initial management of giant omphalocele. *Am J Surg* 2016;211:605–9.
16 Kogut KA, Fiore NF. Nonoperative management of giant omphalocele leading to early fascial closure. *J Pediatr Surg* 2018;53:2404–8.
17 Abello C, A Harding C, P Rios A, *et al*. Management of giant omphalocele with a simple and efficient nonsurgical silo. *J Pediatr Surg* 2021;56:1068-1075.
18 Hijkoop A, Peters NCJ, Lechner RL, *et al*. Omphalocele: from diagnosis to growth and development at 2 years of age. *Arch Dis Child Fetal Neonatal Ed*Ed2019;104:F18–23.
19 Danzer E, Gerdes M, D'Agostino JA, *et al*. Prospective, interdisciplinary follow-up of children with prenatally diagnosed giant omphalocele: short-term neurodevelopmental outcome. *J Pediatr Surg* 2010;45:718–23.
20 Szender JB, Hall KL, Kost ER. A randomized-clinical trial examining a neoprene abdominal binder in gynecologic surgery patients. *Clin Exp Obstet Gynecol* 2014;41:525–9.

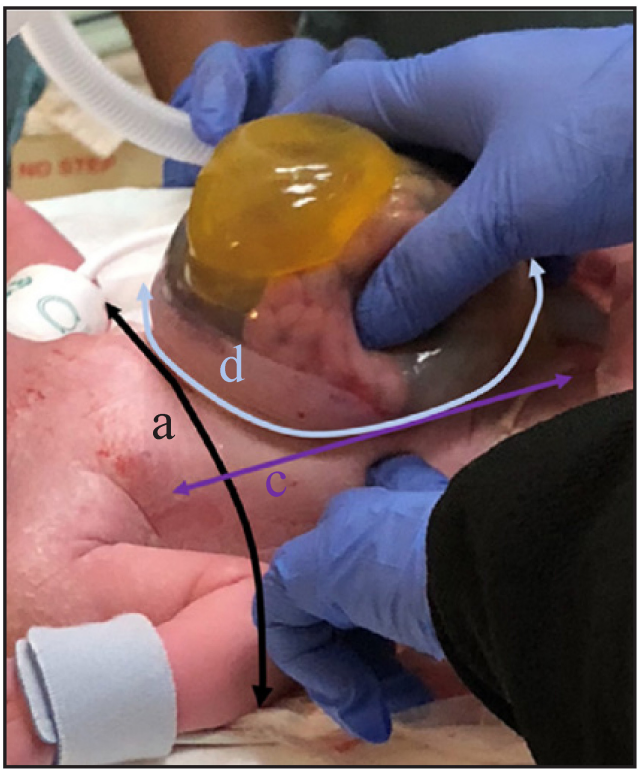











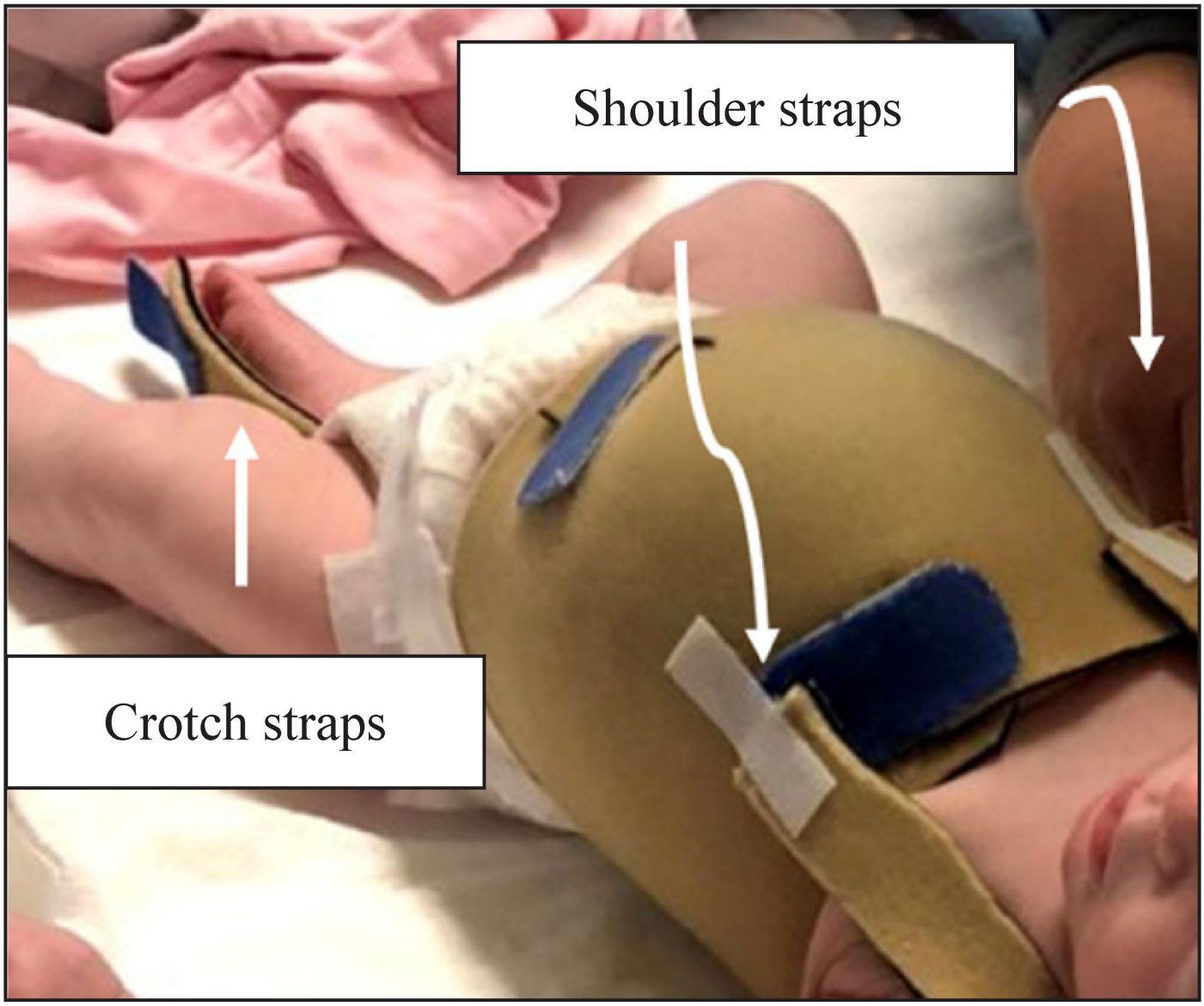

APPENDIX 1: GUIDE ON HOW TO MAKE THE NEOPRENE SILOS

Making a Neoprene Binder to Support and Compress a Giant Omphalocele:

A Guide

Lorena Campbell, MScOT

Dr. Barbara Lelj Garolla, MD, PhD

Victoria General Hospital

Victoria, BC

1. MATERIALS

Neoprene is an effective material to use for supporting and compressing a giant omphalocele as it includes a combination of structure and stretch. Using a neoprene that includes a loop Velcro side allows for extensive adjustability without needing to repeatedly sew Velcro in different locations. We have used the sheets of 1/16" or 1.6mm thick neoprene with pile material on one side (that hook Velcro can attach to).

2. TIME OF INVOLVEMENT

Early referral to the occupational therapist is very helpful. Awareness to expect the baby's arrival before delivery and information around expected day of delivery allows time to ensure materials are available and to prepare to make the binder. Team should contact the occupational therapist when the baby has arrived in the NICU to allow for measurements as soon as the baby is adequately stable.

3. INFANT MEASUREMENTS

The following measurements need to be taken on the infant (Supplementary Figure 1 and Supplementary Table 1):

1. Circumference of the infant's torso both proximal and distal to the omphalocele ("a" and "b")

2. Length of the infant's torso from nipple line to anterior superior iliac crest, provided this is greater than the opening of the abdominal wall defect ("c").

3. Circumference of the neck of the omphalocele ("d").

4. Height of the omphalocele when the entire sac has been confined to the circumference of the omphalocele's neck ("e").

Please note that in practice these measurements have been taken immediately after the omphalocele was wrapped with a length of umbilical cord that was kept intact, then wrapped with sterile gauze while keeping the profile relatively cylindrical with a circumference consistent with the abdominal opening.

SUPPLEMENTARY TABLE 1. Summary of measurements**:**

"a" to "e" – measurements on neonate and omphalocele

"u" to "z" – measurements of the neoprene binding

Label	***Measurements***	***Relationship***
a	Circumference of the infant's torso proximal to the omphalocele	
b	Circumference of the infant's torso distal to the omphalocele	
c	Length of the infant's torso from nipple line to anterior superior iliac crest	
d	Circumference of the neck of the omphalocele	

e	Height of the omphalocele when the entire sac has been confined to the circumference of the omphalocele's neck	
r	Diameter of hole in torso band (piece 1)	
s	Width of compression band (piece 4) = 20% wider than the diameter of the hole in the torso wrap r	s = 1.2r
t	Length of the compression band (piece 4) = 4.5 times the height of the omphalocele (e)	t = 4.5e
u	Length of piece 2 = width of half of the omphalocele	u = d/2
v	Length of piece 3 = width of half of the omphalocele plus 20-30%	v = 1.2u-1.3u
x	height of silo pieces 2 and 3 = height of the contained omphalocele	x =e
y	Torso wrap length (piece 1) = the largest torso circumference plus approximately 10-15% additional length	If a>b → y= 1.15a If b>a → y= 1.15b
w	width of torso wrap (piece 1) = length of the infant's torso	w = c
z	hole in the torso wrap (piece 1) = slightly larger than the neck of the omphalocele.	z = ~1.05d

4. CUTTING THE NEOPRENE TO SIZE.

The neoprene needs to be cut to accommodate the infant's measurements. Please refer to Supplementary Table 1, Figure 1 and Supplementary Figures 1-6 for more details on how to build it. The final product can be seen in Supplementary Figure 3A and 3B. In total 4 pieces needs to be made.

The torso wrap (Piece 1) (Figure 1) needs to be cut to the length ("y") of the largest torso circumference ("a" or "b") plus approximately 10-15% additional length. It needs to be cut to a width ("w") that is the same as the measurement of the length of the infant's torso ("c"). A hole needs to be cut in the torso wrap ("z") which is slightly larger than the neck of the omphalocele ("d"). The hole should be offset to one side so that the wrap will close on a lateral ventral aspect rather over a dorsal aspect, which could cause a point of pressure, and make adjustments to the wrap more challenging. Please note that to slightly reduce heat retention and support infant mobility the width of the portion of the wrap that will cover the back (and especially the shoulder blades) has been shaped to maintain the stability of the wrap (*) while reducing the amount of material. It was useful to start with a slightly larger piece of material and trim down the excess after a trial on the infant.

The first piece of the silo (Piece 2) (Figure 1) is cut to a size "x" in height which is the height of the contained omphalocele "e", and "u" in length which is the width of half of the omphalocele circumference "d"/2. Beveled edges have been cut on both sides of this piece (along the direction of the height of the omphalocele) to reduce any ridges as the second half of the silo overlaps the first.

The second piece of the silo (Piece 3) (Figure 1) is cut to the height "x" which is the height of the contained omphalocele "e", by a width "v" that is approximately 20-30 % more than the width "u" of silo piece number 2 to allow for some overlap of the two pieces.

The compression strap (Piece 4) (Figure 1) is cut to a width ("s") that is approximately 20% wider than the diameter of the hole in the torso wrap and a length ("t") of approximately 4.5 times the height of the contained omphalocele. Small wedges can be cut as shown in Supplementary Figure 4 to create a curvature to the portion of the compression strap that is in contact with the omphalocele. In practice, this has been helpful to prevent the compression strap from sliding out of place as the infants moves or is handled.

5. SEWING THE PIECES TOGETHER.

These pieces need to be sewn together (Supplementary Figure 2-6). Zig zag stitch used on a standard sewing machine with the stretch of the neoprene used to facilitate flat straight lines while sewing, creates a 3-dimensional product as displayed in the images below (Supplementary Figure 2-6). See below for steps by step instruction used to fabricate the binder and corresponding photos of the sewing process.

The first (smaller) silo piece (piece 2) is sewn to the inner circumference of the hole cut into the torso wrap (piece 1) (Supplementary Figure 2). Care is taken to create tight contact between inner rubber cores of the two pieces. The pieces are positioned flat on the sewing machine. Having the soft nylon lining facing up and the pile facing down can make visualization of the seam

and maintenance of a tight seam easier. Some stretching of the hole in the torso wrap is needed to sew the two together effectively and has not been found to create any bunching or irregularities in the seams.

Silo piece 3 is sewn in a similar manner to silo piece 2 (Supplementary Figure 3A and 3B). Starting from either side of the seam attaching silo piece 2 to the torso wrap, ensure that at least 1 cm of overlap is left unsewn creating overlap that prevents the possibility of velcro attachment to the sterile gauze wrap covering the omphalocele (Supplementary Figure 3A). The seam should only be the size of the circumference of the hole cut in the torso wrap with no overlap. When sewing piece 3 into place there should also be at least 1 cm of overlap on the other side that is unsewn. (See the result of sewing the two silo pieces to the torso wrap in Supplementary Figure 3B).

Sewing flat darts in the compression strap creates curvature to accommodate the expected bulge of the omphalocele from the silo with even, gentle pressure (Supplementary Figure 4). This also increases the stability of the compression over the silo and prevents the compression strap from sliding up or down over the omphalocele. The location, length, width, and number of these darts should be determined by the clinician based on the degree of bulge. In our experience a minimum of two darts at each edge of the compression strap was needed. These were created by cutting a narrow triangle into the compression strap (i.e. a 10-20 degree angle 1-2 cm in length). Double pointed ovals can also be cut in the middle of the compression strap on either side of the silo and sewn to increase the amount of curvature (Supplementary Figure 4).

Hook closures around the circumference of the silo, for the torso wrap and for the compression strap, all allow for adjustability so that compression can be increased or backed off based on infant tolerance and stability (Supplementary Figure 5).

6. ADJUSTING AND PROGRESSING THE OMPHALOCELE COMPRESSION.

Use of a neoprene binder that provides support and slow compression to the omphalocele has allowed for parents to hold their infants on the second day of life after the binder has been fabricated and fit. In addition, the neoprene has enough rigidity that the omphalocele did not need any additional vertical support. In the early days it is helpful to frequently check in on fit and function of the binder to revise and progress as tolerated. Twice daily checks by caregivers for skin integrity, dressing changes etc. are beneficial to ensure any issues are attended to promptly.

The medical team will need to decide the most appropriate plan for progressing each infant. Strategies we have used include adding a double layer of 2x2 gauze inside the silo at each shift (creating a stack) as tolerated by the baby and then cutting down the silo approximately when the stack has built to .5 to 1 cm in compressed height (Figure 3A-D). Making the adjustments in this manner allowed for room to easily back off on pressure if the infant showed signs they were experiencing too much pressure (i.e. edema, discoloration, tachycardia or tachypnea).

7. ADDITION OF SHOULDER STRAPS.

As the infants becomes more active and the omphalocele is reduced, we found it helpful to add shoulder straps and a crotch-strap to maintain position of the binding over the omphalocele. Straps can be made of the same materials and either sewn into place or attached with Velcro. Attention should be paid to avoid overlapping material in areas where the infants will put pressure on. Supplementary Figure 6 shows an example of shoulder and crotch straps in place.

8. SUPPLEMENTARY FIGURES

Supplementary Figure 1 – Omphalocele and infants need to be measured to build the neoprene device. a: circumference of the infant's torso proximal to the omphalocele; c: length of the infant's torso from nipple line to anterior superior iliac crest; d: circumference of the neck of the omphalocele; e: height of the omphalocele when the entire sac has been confined to the circumference of the omphalocele's neck. Measurement of the circumference of the infant torso distal to the omphalocele ("b") is not shown in this picture.

Supplementary Figure 2 – Initial assembly of the omphalocele. The smaller of the silos pieces (piece 2) is sewn to the inner circumference of the hole cut into the torso wrap (pieces 1).

Supplementary Figure 3 – Finishing the torso wrap. A. Sewing pieces 1 and 3 – note that suture lines of pieces 2 and 3 do not overlap to avoid pressure points; B. Complete torso wrap and omphalocele silo.

Supplementary Figure 4 – Sewing compression wrap. Darts have been cut and sewed together to allow for curvature of the compression wrap (Piece 4) over the omphalocele.

Supplementary Figure 5 – Bottom left: complete torso wrap and silo; Top left: finished compression strap; Right: fully assembled neoprene binder. Pieces 1, 2, 3 and 4 are marked.

Supplementary Figure 6 – Shoulder and crotch straps are added when the omphalocele is reduced enough in the abdominal cavity that the silos move over the torso. These extra straps also maintained the silo centred when infants become more active.

APPENDIX 2: PARENTAL SURVEY

PARENT SURVEY

1. What is your relationship to the child that underwent Omphalocele repair?

_____

2. Prior to the surgery, what expectations did you have in regard to outcome? *(Please circle one, but then feel free to add other comments if necessary)*

   a) Death
   b) A difficult post-operative recovery with many long-term complications
   c) A difficult post-operative recovery with few/no long-term complications
   d) An easy post-operative recovery with many long-term complications
   e) An easy post-operative recovery with few/no long-term complications

Other comments:
_____

3. Are you satisfied with the surgery?
   Please circle a number. (1: dissatisfied - 10: completely satisfied)

1 2 3 4 5 6 7 8 9 10

Other comments:

_____

4. Were there any aspects of the surgery or recovery that went differently than you expected? Better/worse?

_____

5. How did the overall outcome compare to your expectations prior to surgery? *Please circle a number. (1: worse than expected- 5: exactly as expected- 10: better than expected)*

1 2 3 4 5 6 7 8 9 10

Other comments:

_____

6. How do you think your child is doing now?
   Please circle a number (1: not very well and 10: very well)

1 2 3 4 5 6 7 8 9 10

Other comments:

_____

7. Has having an omphalocele negatively affected your child's quality of life?
   Please circle a number. (1: very much - 10: not at all)

1 2 3 4 5 6 7 8 9 10

Other comments:

_____

8. Has having an infant with an omphalocele negatively affected your quality of life?

Please circle a number. (1: very much - 10: not at all)

1 2 3 4 5 6 7 8 9 10

Other comments:

---

9. Is there anything else you wish to add?
