

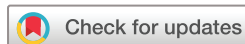Diagnostic value of 3D-FLAIR MRI in children with sudden deafness caused by inner ear hemorrhage

Fu Sheng Gao ¹, Xuan Jia,¹ XiaoHui Ma,¹ Jing Bi,² Qiang Shu ³

To cite: Gao FS, Jia X, Ma X, *et al.* Diagnostic value of 3D-FLAIR MRI in children with sudden deafness caused by inner ear hemorrhage. *World Jnl Ped Surgery* 2021;4:e000280. doi:10.1136/wjps-2021-000280

Received 26 April 2021
Accepted 10 August 2021



© Author(s) (or their employer(s)) 2021. Re-use permitted under CC BY-NC. No commercial re-use. See rights and permissions. Published by BMJ.

¹Department of Radiology, Children's Hospital Zhejiang University School of Medicine, National Clinical Research Center For Child Health, Hangzhou, Zhejiang, China

²Department of Otorhinolaryngology, Children's Hospital Zhejiang University School of Medicine, National Clinical Research Center For Child Health, Hangzhou, Zhejiang, China

³Department of Cardio-Thoracic Surgery, Children's Hospital Zhejiang University School of Medicine, National Clinical Research Center For Child Health, Hangzhou, Zhejiang, China

Correspondence to
Dr Qiang Shu; shuqiang@zju.edu.cn

ABSTRACT

Objective To investigate the diagnostic value of three-dimensional fluid-attenuated inversion recovery (3D-FLAIR) MRI in children with sudden deafness caused by inner ear hemorrhage.

Methods The diagnostic efficacies of three different MRI sequences in the examination of the inner ear for 32 children with sudden deafness were compared. Hearing examination results and 3-month follow-up outcomes were analyzed.

Results The age of 32 children with sudden deafness ranged from 5 to 18 years. MRI was performed from 1 to 18 days after onset. Six cases of sudden deafness caused by inner ear hemorrhage were finally diagnosed clinically. For different MRI sequences, the 3D-FLAIR sequence detected five positive cases; the conventional T1-weighted image sequence also detected five positive cases; but the conventional T2-weighted image sequence only detected three positive cases. The sensitivity and specificity of the 3D-FLAIR sequence in the diagnosis of inner ear hemorrhage were 83.3% (5/6) and 96.2% (25/26), respectively, and the area under the curve value of the receiver operating characteristic curve was 0.897. In the hemorrhage group, all six cases had extremely severe sensorineural hearing loss, and the hearing recovery was ineffective after 3 months of follow-up. The degree of hearing impairment, 3-month short-term treatment efficacy, and 3D-FLAIR MRI in the diagnosis of inner ear hemorrhage between hemorrhage group and non-hemorrhage group were statistically significant ($p=0.043$, $p=0.000$, $p=0.000$).

Conclusions 3D-FLAIR MRI is helpful for the diagnosis of inner ear hemorrhage in children with sudden deafness. Besides, short-term treatment indicates poor effects on children with severe hearing impairment.

INTRODUCTION

Sudden deafness is a common emergency in otorhinolaryngology, and if left untreated after onset, the prognosis may affect the quality of life in the future. Sudden deafness in children and adolescents is defined as sudden onset of unexplained sensorineural hearing loss within 72 hours in children less than 18 years of age.^{1,2} Although the incidence is low, hearing loss in children is generally more severe and the effective rate and recovery rate are lower than those in adults.³ Recent reports

Key messages

What is already known about this subject?

- ▶ Sudden deafness is a common emergency in otolaryngology. If it is not treated in time after the onset, the prognosis may affect the quality of life in the future.
- ▶ Inner ear bleeding can cause sudden deafness in children.
- ▶ It is difficult to detect inner ear bleeding with conventional MRI sequence.

What are the new findings?

- ▶ After the three-dimensional fluid-attenuated inversion recovery (3D-FLAIR) sequence was applied to the inner ear MRI scan, the detection rate of inner ear hemorrhage is significantly improved.
- ▶ This method proved to be equally applicable to children in this study.
- ▶ 3D-FLAIR MRI was similar to T1-weighted image (T1WI) sequence in the diagnosis of inner ear hemorrhage, and it is feasible.

How might it impact on clinical practice in the foreseeable future?

- ▶ 3D-FLAIR MRI examination can diagnose sudden deafness caused by inner ear hemorrhage as the T1WI sequence, and have the efficiency of diagnosing other diseases such as inflammation. Compared with T1WI sequence, it is more suitable than conventional inner ear imaging examination of sudden deafness.

have shown that inner ear hemorrhage can lead to sudden deafness.⁴⁻⁶ However, due to the small anatomy of the inner ear and the limitation in section thickness during the examination, it is difficult to detect inner ear hemorrhage through conventional magnetic resonance imaging (MRI) sequences. With the continuous development of modern imaging technology, the application of the three-dimensional fluid-attenuated inversion recovery (3D-FLAIR) sequence in inner ear MRI has significantly improved the detection rate of inner ear hemorrhage.⁷ At present, there are few studies on MRI special sequence examination of sudden deafness with inner

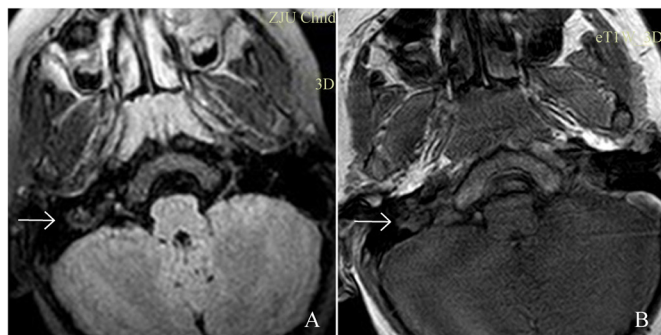


Figure 1 MRI features of the inner ear before treatment in a 7-year-old boy with vestibular hemorrhage in the right ear. (A) Three-dimensional fluid-attenuated inversion recovery (3D-FLAIR) axial image. (B) T1-weighted image (T1WI) axial image. The arrows indicate right vestibular hyperintensity.

ear hemorrhage in children. Herein, we collected the clinical data of 32 children with sudden deafness admitted to the Children's Hospital of Zhejiang University School of Medicine from April 2017 to July 2019. The efficacies of 3D-FLAIR MRI sequence and conventional scanning sequences in detecting inner ear hemorrhage were compared and the correlation between the clinical characteristics and short-term follow-up results was analyzed to explore the diagnostic value of 3D-FLAIR MRI sequence for sudden deafness caused by inner ear hemorrhage in children.

MATERIALS AND METHODS

Clinical data

The 32 children, including 16 males and 16 females, aged 5–18 years, had an average age of 8 years. There were 21 cases (65%) of right ear lesions, 11 cases (35%) of left ear lesions, 9 cases (28.1%) of moderate hearing loss, 5 cases (15.6%) of severe hearing loss, and 18 cases (56.2%) of extremely severe hearing loss. All patients underwent otoscopy and acoustic immittance testing. Tympanography showed type A curve in 23 cases and type AS curve in nine cases.

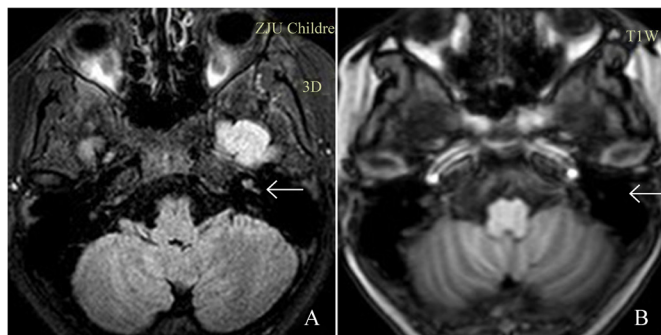


Figure 2 MRI features of the inner ear before treatment in an 8-year-old girl with cochlear hemorrhage in the left ear. (A) Three-dimensional fluid-attenuated inversion recovery (3D-FLAIR) axial image. (B) T1-weighted image (T1WI) axial image. The arrow indicates left cochlear hyperintensity (hyperintensity was not detected in T1WI).

Inclusion criteria

(1) The guidelines for the diagnosis and treatment of sudden deafness formulated by the Chinese Society of Otorhinolaryngology-Head and Neck Surgery in 2015 were referenced.¹ (2) The included patients were 5–18 years old. (3) Patients with diseases such as middle ear lesions and large vestibular aqueduct syndrome and other pathogenic factors such as genetic factors and systemic diseases were excluded. (4) MRI sequences including hydrographic thin-section 3D-FLAIR, T1-weighted image (T1WI), and T2-weighted image (T2WI) were performed.

MRI examination methods of the inner ear

Philips Achieva 3.0T superconducting MRI system was adopted, the head coil was used, and the inner ear routine scan was conducted with the scanning area ranging from the mastoid tip to the upper edge of the petrous bone. Scanning sequence: conventional T1WI/T2WI [repetition time/echo time (TR/TE): 550 ms/14 ms, 4000 ms/80, section thickness 3 mm]. The matrices were all 512×512 with an axial section thickness of 3 mm. Other parameters were shown as follows: inner ear hydrography 3D-DRIVE (TR/TE: 2000 ms/200 ms, voxel size 0.6 mm×0.7 mm×1.0 mm), 1 mm axial and oblique sagittal reformation and maximum signal intensity reformation after scanning; 3D-FLAIR [TR/TE/inversion time (TI): 4800 ms/287 ms/1650 ms, voxel size 0.75 mm×0.75 mm×1.0 mm], 1.5–2 mm axial reformation. Abnormal signal of MRI T1WI/T2WI/3D-FLAIR together with related clinical presentation was considered to be inner ear hemorrhage in children. Clinical diagnosis was finally confirmed after following up the patient's response to treatment.

Grading of hearing loss

According to the criteria³ established by World Health Organization (WHO) in 1997, hearing loss is graded based on the average hearing thresholds at four frequencies, 500, 1000, 2000, and 4000 Hz, in the air conduction pure tone audiometry testing. It is divided into five grades, including grade 0 (normal, ≤25 dB), grade 1 (mild, 26–40 dB), grade 2 (moderate, 41–60 dB), grade 3 (severe, 61–80 dB), and grade 4 (extremely severe, >80 dB). We apply the decibel value of the patient's hearing impairment for statistical calculations.

Response criteria

According to the response criteria established in the Guidelines for the Diagnosis and Treatment of Sudden Deafness (2015) issued by the Editorial Board of Chinese Journal of Otorhinolaryngology-Head and Neck Surgery and the Chinese Society of Otorhinolaryngology-Head and Neck Surgery,³ the response is divided into cure (hearing threshold of each frequency returns to normal or reaches the hearing level before this illness or reaches the healthy ear level), significantly effective (hearing level increases by more than 30 dB on average), effective (hearing level increases by 15–30 dB on average), and

Table 1 MRI diagnosis of inner ear bleeding hemorrhage

		T1WI		T2WI		3D-FLAIR		Total
		(+)	(-)	(+)	(-)	(+)	(-)	
Actual diagnosis	Hemorrhage (+)	5	1	3	3	5	1	6
	Hemorrhage (-)	3	23	2	24	1	25	26

Data were presented as number.

(+), positive; (-), negative; 3D-FLAIR, three-dimensional fluid-attenuated inversion recovery; MRI, magnetic resonance imaging; T1WI, T1-weighted image; T2WI, T2-weighted image.

ineffective (hearing level increases by less than 15 dB). The decibel value of the patient's hearing impairment was used for statistical analysis.

Statistical methods

SPSS (V.23.0, IBM) statistical software was used to analyze and process the data. The χ^2 test was conducted to analyze gender differences, the t-test was used to analyze the differences of age and MRI time, Mann-Whitney U test was performed to compare hearing impairment and treatment efficacy between the two groups. MedCalc (V.15.2.2.0, Schoonjans, Frankakerke, Belgium) was employed to draw receiver operating characteristic (ROC) curves, and the DeLong test was carried out to compare the ROC curve differences. $P < 0.05$ was considered statistically significant.

RESULTS

MRI examination of the inner ear

We divided the included children into hemorrhage group ($n=6$) and non-hemorrhage group ($n=26$). MRI examination was conducted in 1–18 days after onset. Six cases with inner ear hemorrhage were finally diagnosed clinically, and the morphology of the membranous labyrinth was normally detected by 3D reconstruction through inner ear MRI hydrography. Totally, 5 positive cases including three cases located in the vestibule (figure 1A) and 2 cases in the cochlea (figure 1B), as well as 1 negative case were diagnosed through the 3D-FLAIR sequence, while 5 positive cases (figure 2A) including 2 cases located in the vestibule and 3 cases in the cochlea, as well as 1 negative case (figure 2B) were diagnosed through conventional T1WI sequence. Moreover, 3 positive cases including 2 cases in the vestibule and 1 case in the cochlea, together with 3 negative cases were diagnosed through conventional T2WI sequence. We compared the efficacies of the 3D-FLAIR sequence with conventional T1WI sequence

and conventional T2WI sequence in the diagnosis of inner ear hemorrhage. The sensitivity and specificity of the 3D-FLAIR sequence were 83.3% (5/6) and 96.2% (25/26), respectively, and the area under the curve (AUC) value of the ROC curve was 0.897. The conventional T1WI sequence had a sensitivity of 83.3% (5/6), specificity of 88.5% (23/26), and the AUC value of the ROC curve was 0.859. The conventional T2WI sequence had a sensitivity of 50.0% (3/6), a specificity of 92.3% (24/26), and an ROC curve AUC value of 0.712 (tables 1 and 2, and figure 3).

Correlation between hearing examination results, clinical characteristics, and 3-month follow-up results and MRI diagnosis of inner ear hemorrhage in children with sudden deafness

We divided the included children into hemorrhage group ($n=6$) and non-hemorrhage group ($n=26$). There were 6 clinically confirmed cases in the inner ear hemorrhage group, all of which had extremely severe sensorineural hearing loss, including 5 cases of AS type and 1 case of A type in the acoustic impedance tympanic curve. The hemorrhage disappeared after a 3-month follow-up, but the hearing recovery was ineffective. The non-hemorrhage group included 12 cases of extremely severe hearing impairment, 5 cases of severe hearing impairment, and 9 cases of moderate hearing impairment, with 4 cases of AS-type acoustic impedance tympanic curve and 22 cases of type A. The differences of the degree of hearing impairment, 3-month short-term treatment efficacy, and 3D-FLAIR MRI diagnosed inner ear hemorrhage between hemorrhage and non-hemorrhage groups were statistically significant ($p=0.043$, $p=0.000$, $p=0.000$) (table 3).

DISCUSSION

Sudden deafness is a suddenly occurred and unexplained sensorineural hearing loss at all ages with an incidence

Table 2 Diagnostic efficacies of the three MRI sequences in children with sudden deafness

MRI sequence	Sensitivity (%)	Specificity (%)	AUC	95% CI
3D-FLAIR	83.3	96.2	0.897	0.738 to 0.976
T1WI	83.3	88.5	0.859	0.690 to 0.956
T2WI	50.0	92.3	0.712	0.525 to 0.857

AUC, area under the curve; CI, confidence interval; 3D-FLAIR, three-dimensional fluid-attenuated inversion recovery; MRI, magnetic resonance imaging; T1WI, T1-weighted image; T2WI, T2-weighted image.

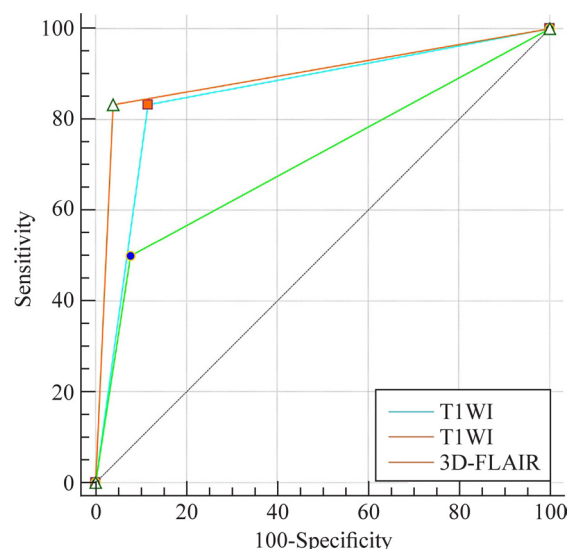


Figure 3 Area under the curve (AUC) of the three MRI sequences. 3D-FLAIR, three-dimensional fluid-attenuated inversion recovery; T1WI, T1-weighted image; T2WI, T2-weighted image.

of 5–20 per 100 000 per year, which has increased in recent years.⁸ The incidence of sudden deafness in children is low, only 1/20 to 1/10 of that in adults.⁹ One of the reasons is that children's expression ability is insufficient, thus unilateral sudden deafness is difficult to be observed, resulting in treatment delay. The other reason is that there are little attention and few studies on idiopathic sudden deafness in children in China. According to the diagnosis and treatment guidelines formulated by the American Society of Otorhinolaryngology in 2012,¹⁰ children with sudden deafness need to undergo audiological examinations such as acoustic impedance and cochlear electromyography, and inner ear MRI examinations, which demonstrates that MRI plays an important role in the diagnosis and treatment of sudden deafness.

There is not a unified evaluation criterion on how to determine inner ear hemorrhage. In the past, the diagnosis of inner ear hemorrhage could only be confirmed

by autopsy.¹¹ With the widespread use of MRI, which is very sensitive to inner ear hemorrhage, it becomes the only method to date that can show labyrinthine hemorrhage.⁷ In this study, based on 32 children with sudden deafness, the diagnostic efficacies of 3D-FLAIR sequence, conventional T1WI sequence, and T2WI sequence were compared and analyzed after the final clinical diagnosis of six cases with sudden deafness caused by inner ear hemorrhage. We found that the sensitivity and specificity of the 3D-FLAIR sequence reached higher than 80%, the AUC value reached 0.897, and the 95% CI was 0.738 to 0.976, which were better than those of both the T1WI sequence and T2WI sequence. The reason is that the 3D-FLAIR sequence can inhibit the signal of the inner ear lymph, thereby better displaying the lesion while cutting the section thinner without increasing the artifact compared with the conventional sequences,^{12,13} which is similar to the results reported by Berrettini *et al*¹⁴ in the study of sudden deafness in adults. The study indicated that the 3D-FLAIR sequence could sensitively indicate the changes of components in the inner ear lymph. T1WI is of great significance in the diagnosis of inner ear hemorrhage. Patients with inner ear hemorrhage often present with high signal intensity on T1WI and show a tendency to decrease during subsequent follow-up, consistent with the gradual absorption and dissipation of methemoglobin in the endolymphatic fluid. Therefore, the final diagnosis of inner ear hemorrhage was appropriate. The sensitivity, specificity, and AUC of the 3D-FLAIR sequence in the study were similar to those of T1WI, but the 95% CI was more reliable. None of the children had a history of otitis media or upper respiratory tract infection, and the abnormal signals disappeared during subsequent follow-up, confirming that the 3D-FLAIR sequence is helpful for the diagnosis of inner ear hemorrhage.

The location of hemorrhage in the six patients with inner ear hemorrhage in this study was not consistent, occurring in the vestibule and cochlea, respectively, and no involvement of the semicircular canal was found. However, the clinical manifestations were the same,

Table 3 Clinical characteristics, audiological characteristics, 3-month follow-up results, and MRI diagnosis of inner ear hemorrhage in hemorrhage and non-hemorrhage groups

	Hemorrhage (n=6)	Non-hemorrhage (n=26)	P value
Age/y*	9.73±3.32	8.06±3.34	0.287
Gender (M/F)†	2/4	14/12	0.909
MRI time/d*	4.17±2.13	6.46±6.02	0.370
3D-FLAIR MRI diagnosis of inner ear hemorrhage (affected ear (R/L/R&L))	1/4	10/6/9	0.000
Degree of hearing impairment (median/IQR)	95/0	87.5/30.5	0.043
Treatment efficacy (median/IQR dB)	0/0	15/5	0.000

*Data were presented with mean±SD. P values were obtained by t-test.

†Data were presented with number. P values were obtained by χ^2 test.

dB, decibel; 3D-FLAIR, three-dimensional fluid-attenuated inversion recovery; F, female; IQR, interquartile range; L, left; M, male; MRI, magnetic resonance imaging; R, right; R&L, right and left.

all manifested as sudden onset of hearing loss in the affected ear. Audiological examination showed extremely severe sensorineural hearing loss in the affected ear, indicating that hearing impairment was severe due to inner ear hemorrhage. It is speculated that as long as a small number of blood components enter the circulating fluid space of the inner ear, the stable body fluid environment of inner and outer hair cells will change, and then irreversible damage and even necrosis will occur, suggesting that in patients with extremely severe sudden deafness, the proportion of inner ear hemorrhage is relatively high. Therefore, if audiological examination of children with sudden deafness reveals extremely severe sensorineural hearing loss, inner ear MRI is recommended to rule out inner ear hemorrhage. This is consistent with the findings of Xuan *et al.*⁵ indicating that although the incidence of sudden deafness caused by inner ear hemorrhage in children is low, the pathogenetic form is similar to that of adults.

In this study, we found that conventional treatment was not satisfactory in six children with inner ear hemorrhage, and the hearing recovery was ineffective during the 3-month short-term follow-up. The treatment effect and prognosis were poor in patients with inner ear hemorrhage. The prognosis is worse than that reported by Xihang *et al.*⁴ and Xuan *et al.*⁵ in the study of sudden deafness caused by inner ear hemorrhage in adults. It is speculated that the hormone level, living environment, learning, and psychological pressure of children may cause poor treatment compliance or poor drug response.¹⁵ Although the 3D-FLAIR sequence is helpful for the diagnosis of sudden deafness caused by inner ear hemorrhage in children and its correlation with poor prognosis, due to the small sample size, the detailed relationship between inner ear hyperintensity and clinical manifestations and whether the different distribution of hyperintensity is associated with clinical manifestations still need further study.

In summary, this study shows that 3D-FLAIR MRI examination is helpful for the diagnosis of inner ear hemorrhage in children with sudden deafness. Besides, short-term treatment indicates poor effects on children with severe hearing impairment.

Contributors FSG contributed to investigation, data curation and writing—original draft. XJ was responsible for data curation, project administration, resources, supervision, visualization and writing—review and editing. XM carried out data curation, project administration, resources, supervision, validation, visualization and writing—review and editing. JB performed data curation, project administration, resources and supervision. QS was involved in conceptualization, methodology, supervision, validation and writing—review and editing.

Funding The authors have not declared a specific grant for this research from any funding agency in the public, commercial or not-for-profit sectors.

Competing interests QS is the Editor in Chief for World Journal of Pediatric Surgery. The paper was handled by the other Editor and has undergone rigorous

peer review process. QS was not involved in the journal's review of, or decisions related to, this manuscript.

Patient consent for publication Not required.

Ethics approval This study has been approved by the Ethics Committee of the Children's Hospital, Zhejiang University School of Medicine.

Provenance and peer review Not commissioned; externally peer reviewed.

Data availability statement All data relevant to the study are included in the article or uploaded as supplemental information.

Open access This is an open access article distributed in accordance with the Creative Commons Attribution Non Commercial (CC BY-NC 4.0) license, which permits others to distribute, remix, adapt, build upon this work non-commercially, and license their derivative works on different terms, provided the original work is properly cited, appropriate credit is given, any changes made indicated, and the use is non-commercial. See: <http://creativecommons.org/licenses/by-nc/4.0/>.

ORCID iDs

Fu Sheng Gao <http://orcid.org/0000-0001-9935-9715>

Qiang Shu <http://orcid.org/0000-0002-4106-6255>

REFERENCES

- Editorial Board of Chinese Journal of Otorhinolaryngology Head and Neck Surgery; Society of Otorhinolaryngology Head and Neck Surgery, Chinese Medical Association. [Guideline of diagnosis and treatment of sudden deafness (2015)]. *Zhonghua Er Bi Yan Hou Tou Jing Wai Ke Za Zhi* 2015;50:443–7.
- Jifei WZ, Qiuju W. Diagnosis and treatment of sudden deafness and vertigo in Children- minutes of symposium of Beijing hearing screening diagnostic center for children aged 0-6 years in the first quarter of 2013. *Chinese Journal of Otolaryngology* 2013;11:170.
- Chinese Society of otorhinolaryngology, editorial board of Chinese Journal of otorhinolaryngology. diagnostic basis and therapeutic classification of sudden deafness. *Chinese Journal of Otorhinolaryngology* 1977;32:72.
- Xihang C, Changchang L, Zaiming F. Analysis of clinical characteristics of patients with sudden deafness caused by inner ear hemorrhage. *Chinese Journal of Otorhinolaryngology, Head and Neck Surgery* 2015;12:996–1000.
- Xuan W, Liang S, Qianqian C, *et al.* Clinical analysis of eight cases of sudden deafness caused by inner ear hemorrhage. *Chinese Journal of Otorhinolaryngology Head and Neck Surgery* 2015;7:540–5.
- Kim DS, Park DW, Kim TY, *et al.* Characteristic MR findings suggesting presumed labyrinthine hemorrhage. *Acta Otolaryngol* 2017;137:1226–32.
- Fitzgerald DC, Mark AS. MRI in sudden sensorineural hearing loss. *Otolaryngol Head Neck Surg* 1998;118:737–8.
- Schreiber BE, Agrup C, Haskard DO, *et al.* Sudden sensorineural hearing loss. *The Lancet* 2010;375:1203–11.
- Chen Y-S, Emmerling O, Ilgner J, *et al.* Idiopathic sudden sensorineural hearing loss in children. *Int J Pediatr Otorhinolaryngol* 2005;69:817–21.
- Stachler RJ, Chandrasekhar SS, Archer SM, *et al.* Clinical practice guideline: sudden hearing loss. *Otolaryngol Head Neck Surg* 2012;146:S1–35.
- Johnson A, Hawke M, Berger G. Sudden deafness and vertigo due to inner ear hemorrhage—a temporal bone case report. *J Otolaryngol* 1984;13:201–7.
- Naganawa S, Nakashima T. Cutting edge of inner ear MRI. *Acta Otolaryngol Suppl* 2009;15–21.
- Naganawa S. The technical and clinical features of 3D-FLAIR in neuroimaging. *Magn Reson Med Sci* 2015;14:93–106.
- Berrettini S, Seccia V, Fortunato S, *et al.* Analysis of the 3-dimensional fluid-attenuated inversion-recovery (3D-FLAIR) sequence in idiopathic sudden sensorineural hearing loss. *JAMA Otolaryngol Head Neck Surg* 2013;139:456–64.
- Jing B, Zhiying Z, Ai J. Clinical analysis and short-term efficacy observation of sudden deafness in children and adolescents. *Chinese Journal of Otolaryngology* 2018;16:43–7.